

Am 65-4

**CRANIAL IMPEDANCE  
PLETHYSMOGRAPHY —  
RHEOENCEPHALOGRAPHY AS A  
METHOD OF DETECTION OF  
CEREBROVASCULAR DISEASE\***

J. H. SEIPEL, S. A. R. ZIEMNOWICZ, AND D. S. O'DOHERTY

*Reprinted from*

**CEREBRAL ISCHEMIA**

*Compiled and Edited by*

Ernst Simonson, M.D. and Thomas Hodge McGavack, M.D.

CHARLES C THOMAS : PUBLISHER • *Springfield : Illinois : U.S.A.*

---

**CRANIAL IMPEDANCE  
PLETHYSMOGRAPHY —  
RHOENCEPHALOGRAPHY AS A  
METHOD OF DETECTION OF  
CEREBROVASCULAR DISEASE\***

J. H. SEIPEL, S. A. R. ZIEMNOWICZ, AND D. S. O'DOHERTY

**C**EREBROVASCULAR DISEASE ranks third in causes of death in the general population (1). Many of these approximately 200,000 fatalities (1) and the accompanying larger number who suffer sublethal central nervous system damage are potentially salvageable if proper therapy can be instituted sufficiently early; those patients suffering undiagnosed extracranial arterial occlusions are the most tragic, for this disease can be treated surgically. These patients have one factor in common—that of impairment of cerebral blood flow to the point where neuron loss took place.

There is an obvious need for a simple quick method that will give a clinically reliable indication of the intracranial circulation, preferably in both hemispheres simultaneously.

The purpose of this paper is to demonstrate by the presentation of several cases that rheoencephalography, no matter what its tracings may represent in the way of biological variables, can be used clinically as though it monitors intracranial circulation (2, 3).

The electrode placement for rheoencephalography is indicated in Figure 1.

**Cases:**

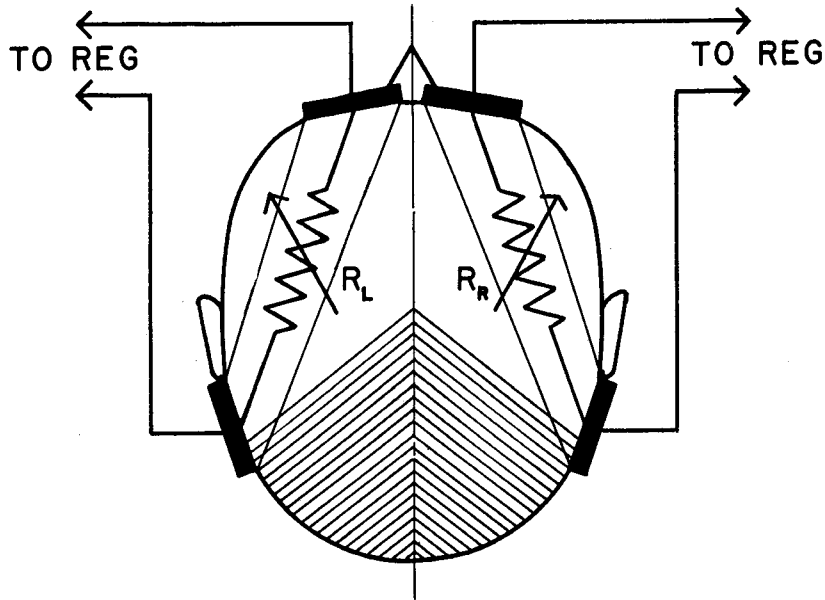
*Case No. 1:* The first case is that of R. K., a fifty year old white male who experienced a suddenly occurring fifteen minute episode

---

\* A contribution from the Georgetown Clinical Research Institute of the Federal Aviation Agency, and the Neurological Research Laboratory of the Georgetown University Hospital.

of unconsciousness followed by right hemiparesis and partial aphasia which cleared in several hours. At this time a bruit was noted in the region of the left ear. Arteriography was performed and disclosed an inoperable high left internal carotid occlusion (Fig. 2).

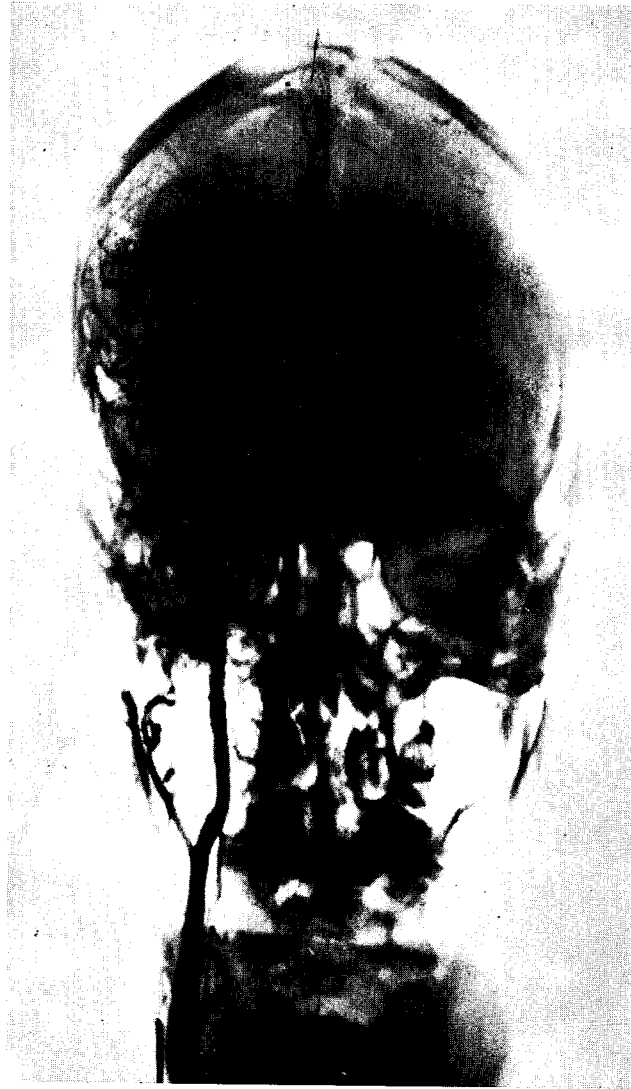The resting tracing indicates that the instantaneous blood volume on the two sides of the brain is essentially equal; however, on right carotid compression the wave form radically decays, both amplitudes decrease but much more so on the left, and the left



## ELECTRODE PLACEMENT

Fig. 1. Placement of electrodes for rheoencephalography. Two electrodes are placed on the forehead and another two over the mastoids, each lateral pair forming a separate circuit. The electrodes are placed so as to align the included volume just above the base of the skull excluding as much as possible the external carotid and basilar arterial fields. The lines on the diagram connecting the electrodes delineate the presumed volume monitored; the latter is represented by the symbol for a variable resistance. It is particularly important to note that these electrodes must be positioned in as identically symmetrical positions as possible; the tracings are comparable only if equivalent volumes are monitored.

The diagnosis of falsely localizing signs secondary to hemorrhage on the right was made; the patient was transferred to this hospital and explored. At operation a subdural and subarachnoid collection of clot and blood measuring 8 mm. in thickness and 150 mm. in diameter overlying the anterior and lateral aspects of the



right frontal lobe was found arising from the Sylvian fissure. Old clot extended down this fissure and back along the base of the brain to the peduncular region where it pressed the left peduncle against the tentorium and accounted for the misleading neurological signs. The aneurysm was clipped; the patient recovered with minor residua secondary to the operative trauma.

Once again it is impossible for these tracings to have arisen from the external circulation. This case is, to the best of my knowledge, the first case in which rheoencephalography was used as the deciding factor in a clinical emergency in the United States; rheoencephalography was first used by one of our group (S.Z.) in November of 1960 to successfully lateralize a tumor despite an equivocal clinical picture.

These cases are presented to indicate the potential value to clinical medicine of this overlooked method and to stimulate others in its investigation and use. While the exact significance of these tracings is uncertain it is evident that rheoencephalo-

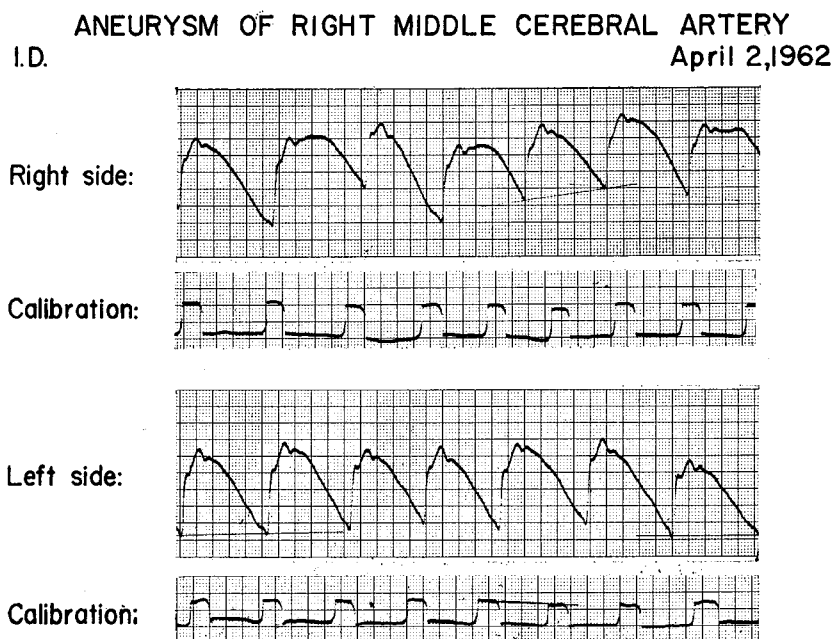


Fig. 9. Case No. 3 — Rheoencephalogram illustrating the effect of increased intracranial pressure and restricted flow on the right.

various sizes and shapes of electrodes, different locations of electrodes for placing, etc. I would like to show two slides, illustrative of the controversial nature of this method and some of the difficulties involved in its application. These tracings were selected to show similarity and dissimilarity of the contours of

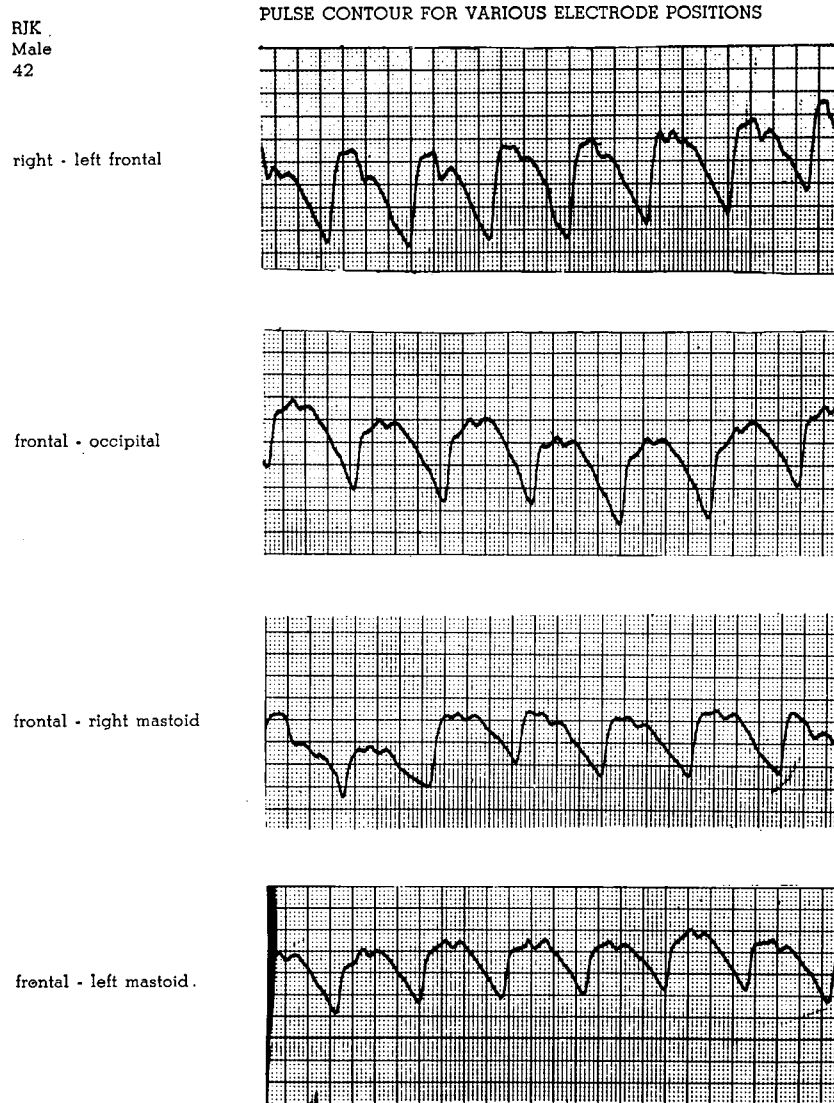


Fig. 1

impedance plethysmograms taken from different electrode locations. The first figure (Fig. 1) shows the impedance plethysmogram of a normal, healthy man, forty-two years of age with tracings taken in the order from top to bottom, 1) frontal-frontal, 2) frontal-occipital, 3) frontal-right mastoid, and 4) frontal-left mastoid. There is a general similarity of the contour of all leads. Thus, the contour does not differentiate extra-cranial and intracranial circulation; the tracings may represent a mixture of both. While the intracranial circulation is many times larger than the extracranial circulation, this fact may not be reflected in the record. The electrical field distribution between electrodes

## PULSE CONTOUR AT VARIOUS ELECTRODE POSITIONS

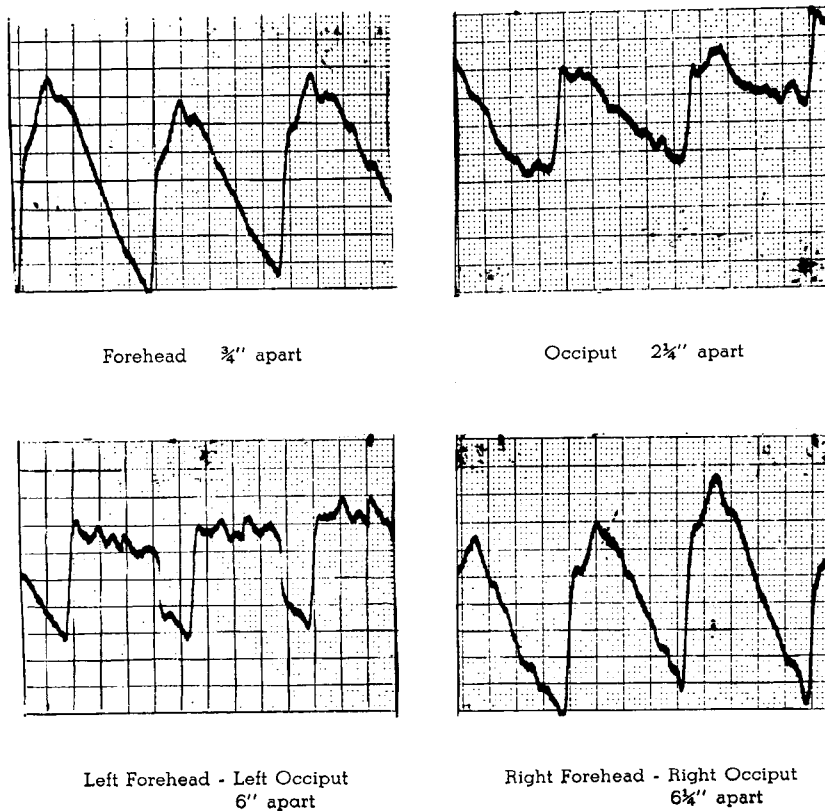


Fig. 2

placed on the scalp in man is not precisely known. Moskalenko and Naumenko found up to 50 per cent contamination by extracranial circulation. Differences between the contours of the extracranial and intracranial pulses are to be expected. The next tracing (Fig. 2) shows the cranial impedance plethysmogram of a normal forty-five year old man. The electrode locations were: for the upper left tracing, on the forehead; for the upper right tracing, on the occipital region; for the lower left tracing, on the left forehead-left occiput; and the lower right tracing, on the right forehead-right occiput. There are great differences in contour among the tracings taken at different locations. Such differences have been considered by some clinicians as indicative of cerebrovascular disease, but we found a large variation in contour among 200 older normal men. This material is now in the process of statistical evaluation. Perhaps one might argue that the large differences between the contour from different electrode sites may be an early sign of cerebrovascular disease. However, in this case, there was no development of overt clinical symptoms of cardiovascular or cerebrovascular disease; the subjects remained entirely asymptomatic.

We have performed a substantial number of unpublished experiments regarding the effects of right and left carotid sinus pressure in normal subjects. The results were quite variable, as may be expected from animal experiments. Again, the normal variability should be the basis for clinical application, but so far as is known to me, no statistical analysis of the effects of carotid pressure based on an adequate normal sample has yet been published.

In a recent series of fifteen normal subjects, we found no statistically significant change in the impedance plethysmograms from forehead-mastoid locations, i.e., the same locations which Doctor Jenkner and Doctor Seipel have been using, while the subjects were breathing a mixture of 6 per cent CO<sub>2</sub> and air. According to Kety and Schmidt's data, an increase of intracranial circulation of about 100 per cent should have been expected. Photoelectrically recorded skin circulation of the scalp with the pickup placed between the impedance plethysmogram electrodes increased slightly during breathing of 6% CO<sub>2</sub>. Our results in-



dicating considerable contamination of intracranial by extracranial circulation. It is not unusual that divergent results are obtained with variations in approach. Doctor Seipel's data will contribute importantly to any general evaluation of the problem. Cranial impedance plethysmography is potentially a very useful method, but it needs further exploration.

DR. SEIPEL:

To all of which I say "Amen!"

DR. KENNETH LIFSHITZ: (*Monsey, New York*)

I wonder if Doctor Simonson and Doctor Seipel would comment on the sizes of the electrodes they have been using? We have been working with rheoencephalography for about three years, and we find variations in results which depend upon the size of the electrode used.

DR. SEIPEL:

The same type and amplitude of pulse are obtained with a wide range of electrode sizes. Therefore, for the purpose of comparing several instruments with each other, we are now using the standard Jenkner aluminum blocks. In monitoring surgical procedures, we have also used the "Telemedics" adhesive plaster stick-on electrodes which work quite well.

DR. SIMONSON:

Doctor Otto Schmitt and I have done quite extensive experiments on the shape and size of electrodes; the sites of electrode location, pressures on electrodes equal or exceeding the systolic blood pressure, etc. There is a critical size for the electrodes (about 10 mm<sup>2</sup>), beyond which there is little variation. These experiments were mainly performed for possible differentiation between extracranial and intracranial circulation, but the results were not definite.

DR. OBRIST:

The question I would like to ask is in connection with cerebral blood flow. I have heard you use the words blood flow and I have seen the expression in the literature. It occurs to me that this technique is primarily a measurement of blood volume, or, at most, of relative changes in blood volume. I wonder if it isn't a little misleading to use the term, "blood flow?"

---



---

