

DOT/FAA/AM-98/25

Office of Aviation Medicine
Washington, D.C. 20591

The Aeromedical Certification of Photorefractive Keratectomy in Civil Aviation: A Reference Guide

Van B. Nakagawara
Kathryn J. Wood
Civil Aeromedical Institute
Federal Aviation Administration
Oklahoma City, OK 73125

September 1998

Final Report

This document is available to the public
through the National Technical Information
Service, Springfield, Virginia 22161.



U.S. Department
of Transportation

**Federal Aviation
Administration**

NOTICE

This document is disseminated under the sponsorship of the U.S. Department of Transportation in the interest of information exchange. The United States Government assumes no liability for the contents thereof.

1. Report No. DOT/FAA/AM-98/25		2. Government Accession No.		3. Recipient's Catalog No.	
4. Title and Subtitle The Aeromedical Certification of Photorefractive Keratectomy in Civil Aviation: A Reference Guide				5. Report Date September 1998	
				6. Performing Organization Code	
7. Author(s) Nakagawara, V.B., and Wood, K.J.				8. Performing Organization Report No.	
9. Performing Organization Name and Address FAA Civil Aeromedical Institute P.O. Box 25082 Oklahoma City, OK 73125				10. Work Unit No. (TRAIS)	
				11. Contract or Grant No.	
12. Sponsoring Agency name and Address Office of Aviation Medicine Federal Aviation Administration 800 Independence Ave, S.W. Washington, D.C. 20591				13. Type of Report and Period Covered	
				14. Sponsoring Agency Code	
15. Supplemental Notes This work was performed under task AM-B-98-TOX-203					
16. Abstract The use of surgery to correct refractive errors continues to evolve at a significant pace. Radial keratotomy (RK), the first widely accepted refractive surgical procedure, involves making radial incisions on the peripheral cornea. These incisions weaken the cornea and allow intraocular pressure to push the peripheral cornea out, flattening the apex and reducing refractive power. There are many disadvantages with RK that raise concerns regarding its use in the aviation environment. These include: progressive hyperopic shifts, reduced corneal strength, fluctuation of vision, glare, poor refractive predictability and altitude-induced corneal changes. In October 1995, the Food and Drug Administration approved the use of the excimer laser to perform photorefractive keratectomy (PRK) to reshape the anterior curvature of the cornea. Since that time, PRK has become the refractive surgical procedure of choice. It has been reported that for low to moderate levels of myopia there is greater predictability, no fluctuation of vision or reduction in corneal strength, and about 85% of patients have uncorrected visual acuity of 20/40 or better. As with RK, there are aspects of PRK that raise concerns about its use in the aviation environment. Some of these include: night vision problems (e.g., glare, halos around lights, haze, starbursts, and dim lighting difficulties), reduced contrast sensitivity, stability of refraction, reduced best-corrected visual acuity, and induced anisometropia. Using a mathematical model, it was estimated that by the year 2000 there may be over 1,200 civil airmen who elect to have PRK performed. To provide the aeromedical community with information to formulate administrative decisions and policies associated with this new refractive surgical procedure, this paper reviews the results of clinical trials on PRK and discusses its applicability in aviation.					
17. Key Words Aviation Vision; Refractive Surgery; Radial Keratotomy (RK); Photorefractive Keratectomy (PRK)				18. Distribution Statement Document is available to the public through the National Technical Information Service; Springfield, Virginia 22161	
19. Security Classif. (of this report) Unclassified		20. Security Classif. (of this page) Unclassified		21. No. of Pages 49	
22. Price					

FOREWORD

In the past 10 years, numerous refractive surgical procedures have risen to levels of transient popularity, only to quietly disappear with few publications stating why they were abandoned. The urge to use the latest surgical technique is particularly strong in refractive surgery because development is rapid, surgeons want to offer patients the most current advantages, there is a prevalent attitude of hype, competition is intense to gain professional leadership, and the economic stakes are high for both practitioners and industry. These factors push unproven techniques into clinical use before their advantages and disadvantages are well defined, creating a pattern of free market madness that is unhealthy for refractive surgeons and patients (1).

—George O. Waring III, M.D.

TABLE OF CONTENTS

	Page
I. INTRODUCTION	1
A. Myopia	1
B. Hyperopia	3
C. Astigmatism	3
II. REFRACTIVE TECHNIQUES	4
A. Non-Surgical Techniques and Surgical Procedures Not Involving the Cornea	4
1. Orthokeratology	4
2. Cycloplegia	4
3. Clear lens extraction	4
4. Scleral reinforcement	4
B. Refractive Procedures Involving the Cornea	5
1. Keratomileusis	5
2. Keratophakia	5
3. Epikeratophakia	5
4. Stromal thermokeratoplasty	5
5. Intrastromal corneal ring (ICR)	5
III. RADIAL KERATOTOMY	5
A. Historical and Procedural Process	5
B. Complications	6
1. Anesthesia	6
2. Operative	6
3. Intraocular and eyelid complications	6
4. Corneal	6
5. Refractive	7
6. Visual performance	7
C. Advantages	7
1. Rapid recovery	7
2. Established safety	7
3. Procedures for astigmatism	7
4. Cost	7
D. Disadvantages	7
1. Refractive	7
2. Limitations	7
3. Predictability	7
E. Certification of Pilot Applicants with RK	7
1. Certification process	7
• Historical	7
• Present	7
2. Considerations to aviation	8
IV. PHOTOREFRACTIVE KERATECTOMY	8
A. Historical and Procedural Process	8
1. Epithelial removal	10
2. Ablation zone diameter	10

3.	Centration of ablation zone	10
4.	Epithelial and stromal changes	11
5.	Corneal endothelial changes	11
B.	Selection Criteria	11
1.	Post-operative vision	11
2.	Sex	12
3.	Age	12
4.	Ocular/systemic disease	12
5.	Amount of myopia	12
6.	Astigmatism	12
7.	Binocularity	12
8.	Contact lens wear	12
9.	Occupation	12
10.	Pupil size	13
C.	Clinical Studies	13
1.	Stability	13
2.	Efficacy	13
3.	Safety	13
	• Loss of BCVA	13
	• Decrease in contrast sensitivity	14
	• Ultraviolet-C (UV) exposure	14
4.	Side-effects	14
	• Thermal damage	14
5.	Specific complications	15
	• Healing responses	15
	• Post-surgical corneal opacities	15
	• Glare/Halos	15
	• Pain	15
	• Corneal ulceration	16
	• Corneal sensitivity	16
	• Sterile corneal infiltrates	16
	• Regression	16
	• Over/Under correction	16
	• Corticosteroids	16
	• Non-steroidal anti-inflammatory agents	17
	• Diurnal fluctuation in vision	17
	• Central islands	17
	• Subretinal hemorrhages	18
	• Other complications	18
D.	Future Developments	18
V.	AEROMEDICAL ISSUES	19
A.	Certification of Pilot Applicants	19
B.	Factors Favoring PRK in Civil Airmen	21
C.	Aeromedical Certification Recommendations	21
D.	Options Under Consideration by FAA for Evaluation of Applicants With PRK	22

VI. SUMMARY	23
VII. REFERENCES	24
VIII. APPENDIX A	A-1
A. Non-Surgical Procedures	A-1
Orthokeratology	A-1
Cycloplegia	A-1
B. Surgical Procedures Not Involving the Cornea	A-1
Clear Lens Extraction	A-1
Scleral Reinforcement	A-1
C. Surgical Procedures Involving the Cornea	A-2
Keratomileusis	A-2
Keratophakia	A-3
Epikeratophakia	A-3
Stromal Thermokeratoplasty	A-4
Intrastromal Corneal Ring	A-5

LIST OF ACRONYMS

ALK	Automated Lamellar Keratoplasty
BCVA	Best-Corrected Visual Acuity
CSF	Contrast Sensitivity Function
D	Diopter
FAA	Federal Aviation Administration
FDA	Food & Drug Administration
IFR	Instrument Flight Rules
ICR	Intrastromal Corneal Ring
LASIK	Laser-Assisted in Situ Keratomileusis
LTK	Laser Thermokeratoplasty
MM	Millimeters
μm	Microns
NM	Nanometer
PPP	Pillar Point Partners
PRK	Photorefractive Keratectomy
PTK	Phototherapeutic Keratectomy
RK	Radial Keratotomy
UV	Ultraviolet

THE AEROMEDICAL CERTIFICATION OF PHOTOREFRACTIVE KERATECTOMY IN CIVIL AVIATION: A REFERENCE GUIDE

I. INTRODUCTION

Refractive error is a defect in the eye that prevents light rays from being brought to a single focus on the retina. Refractive errors are common conditions in which corrective lenses (e.g., glasses, contact lenses) are needed to see clearly. There are three refractive conditions: myopia (nearsightedness), hyperopia (farsightedness), and astigmatism (visual blurring at all distances). Although not a refractive condition, presbyopia (decreased focusing ability), which normally occurs around age 40 years, results in blurred vision at near distances, requiring bifocals or reading glasses.

There are approximately 145 million Americans who are dependent upon spectacles or contact lenses to achieve a quality of vision satisfactory for their daily needs. This conservatively represents 54.6% of the United States population. About 10%, some 26.5 million Americans, wear contact lenses (2).

It is anticipated that, in the next decade, there will be increasing market pressure to provide those with refractive error a lifestyle free of spectacles and contact lenses. Lifestyle improvement is a major factor influencing patients to seek alternative methods of refractive correction (i.e., refractive surgery). An industry analyst predicts that, within the next 5 years, between one and three million photorefractive keratectomy (PRK) procedures will be performed annually, with about three million Americans having been treated (3). One leading refractive surgeon expects PRK to become a rite of passage like braces, a driver's license, college, and then PRK (3).

A. MYOPIA

Myopia, or nearsightedness, is a condition in which parallel rays of light from an object being viewed come to focus at a point just in front of the retina (see Figure 1). There are two types of myopia: 1) axial, in which the eye is too long for the normal refractive power of the lens and cornea; and 2) component, which results from a change in the curvature of the cornea/lens or in the index of refraction of the cornea/lens. For example, diabetes (in which the crystalline lens loses water due to the high

level of blood sugar in the anterior chamber) and cataract (an opacity or cloudiness of the crystalline lens) may change the index of refraction of the lens. Almost everything has been blamed as a cause of myopia, including diet, obesity, allergy, light conditions, vitamin deficiencies, and even wearing glasses too much or too little. Controversy and heated debate continues on whether excessive close work or reading is a primary cause of myopia. Myopia is rare at birth, normally manifesting itself after the 4th year of life, with progression relatively constant until the time of puberty, when it may progress rapidly. Normally, myopia becomes stable when full maturity is reached. Therefore, between the ages of 20 and 40 years, the myope's correction may remain essentially unchanged (4).

Even a relatively small amount of myopia results in distant objects being considerably blurred. For example, a -1.00 Diopter (D) myopic refractive error would result in unaided vision of 20/40 to 20/60 Snellen acuity. While eyeglasses or contact lenses are the primary treatment for myopia, they can be a hindrance in some occupations or recreational activities. In addition, high myopic lenses have thick edges and the optical image is reduced by minification and optical aberrations. It is estimated that about 25% (75 million) of the population in North America are myopic and, of these, more than 60 million have < 6.00 D of myopia (5).

Myopia is a frequent phenomenon in all social categories, but incidence varies depending on many factors (see Table 1). Myopia has been found to be patterned in its occurrences in different races and ethnic groups. Blacks, whether in Africa or in the United States, have a low prevalence of myopia. Asians have been found to have a prevalence of myopia as high as 40%, compared to only 20% in whites. The severity of myopia is associated with educational attainment. Myopia has also been found to be positively associated with social class, degree of urbanization of place of residence, and level of economic development of the region or country of residence. There is an increase in the

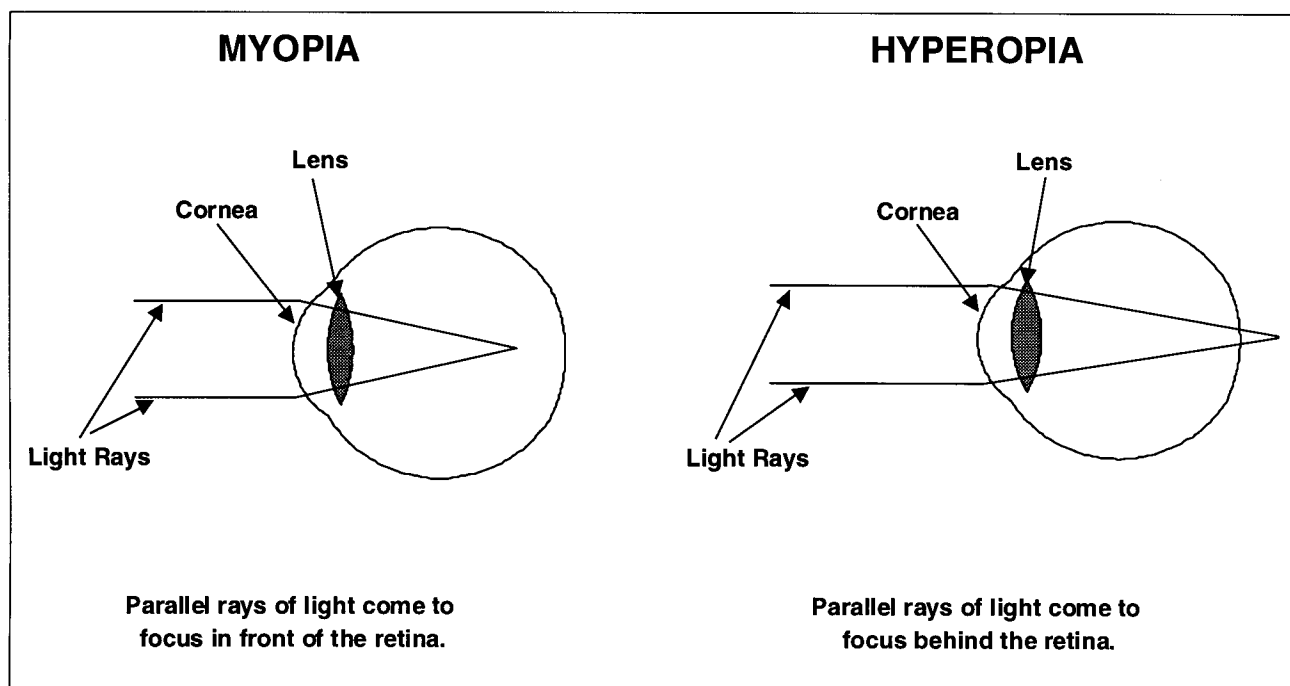


FIGURE 1

Table 1: Frequency of Myopia by Social Categories (N = 13,536)								
Sex		% Myopic		Female		% Myopic		
Male		28.4		Female		35.0		
Race		% Myopic		Non-black		% Myopic		
Black		25.1		Non-black		32.7		
Region	% Myopic	Midwest		% Myopic	South	% Myopic	West	% Myopic
Northeast	32.4	Midwest		35.7	South	24.1	West	33.4
Family Income		% Myopic		Family Income		% Myopic		
<\$500		16.8		\$4,000 - \$4,999		31.5		
\$500 - \$999		20.9		\$5,000 - \$6,999		31.2		
\$1,000 - \$1,999		26.5		\$7,000 - \$9,999		32.3		
\$2,000 - \$2,999		26.7		\$10,000 - 14,999		36.8		
\$3,000 - \$3,999		28.1		≥\$15,000.		35.1		
Grade in School		% Myopic		Grade in School		% Myopic		
≤ 6th		26.4		10th		32.2		
7th		28.9		11th		35.4		
8th		31.3		≥ 12th		35.0		
9th		32.8						
Age (years)		% Myopic		Age (years)		% Myopic		
12		29.9		15		31.9		
13		31.5		16		33.0		
14		31.2		17		33.2		
Reading Test (deciles)		% Myopic		Reading Test (deciles)		% Myopic		
1 (low)		19.7		6		32.4		
2		24.9		7		31.0		
3		27.6		8		38.1		
4		30.9		9		37.5		
5		31.3		10 (high)		45.3		
Time spent reading magazines, books, newspapers in a typical day								
% Myopic		1 - 3 hours		% Myopic		% Myopic		
< 1 hour		27.7		32.8		> 3 hours		34.6

Source of data: National Health Examination Survey of 12 to 17 year olds, 1966-1970.

(Reprinted from Stein HA, Cheskes A, Stein RM. *The excimer: Fundamental and clinical use*. Thorofare, NJ: Slack Inc. 1995, 22.)

prevalence of myopia as average family income rises. For the total U.S. population, the rates of myopia increased from 18% to 36% as family income increased (5).

B. HYPEROPIA

Hyperopia, or farsightedness, is a condition in which parallel rays of light from an object being viewed come to focus at a point behind the retina (see Figure 1). The lens of the eye lacks sufficient converging power. Usually, the chief cause of hyperopia is a shortening of the anteroposterior axis of the eye (axial hyperopia) (i.e., eye is smaller than normal). Another cause of hyperopia is when the front surface of the cornea or lens has less curvature than normal (curvature hyperopia). At birth, most eyes are hyperopic (about 2.00 or 3.00 D). With aging, the eye normally lengthens. (Note: Each mm that the eye is too short is equal to 3.00 D of hyperopic refractive change (4).) Statistics are vague on the prevalence of hyperopia, since many studies incorrectly incorporate presbyopia, which also requires plus power lenses, as part of the total percentage of hyperopia in the population.

C. ASTIGMATISM

Astigmatism, or blurred vision at all distances, is a condition in which rays of light from an object being viewed are not refracted equally in all directions, so that a point focus on the retina is not attained. The most

common type is regular astigmatism, which can be subdivided into: simple, one focal point always falls on the retina while the other focal point is behind (simple hyperopic) or in front (simple myopic) of the retina (see Figure 2); compound, light rays are refracted so that both focal points lie either behind (compound hyperopic) or in front (compound myopic) of the retina (see Figure 3); and, mixed, one focal point lies behind and the other focal point lies in front of the retina (see Figure 3). Astigmatism is normally the result of the radius of curvature of the cornea not being equal in all directions. Although at birth the cornea is usually spherical, by 4 years of age the cornea shape changes. With-the-rule astigmatism occurs as the horizontal axis of the cornea steepens with age (horizontal light rays refracted more sharply than vertical rays) (4). When the vertical axis of the cornea is refracted more steeply than the horizontal axis, the result is against-the-rule astigmatism. Irregular astigmatism most often occurs if the cornea has been damaged by trauma, inflammation, scar tissue, or developmental anomalies. This cannot be completely corrected by ophthalmic spectacle lenses, due to the irregular corneal surface and the lack of any geometric form. Approximately 63.2% of the population has astigmatism; of those, 59.8% have astigmatism < 3.00 D (48% ≤ 1.00 D, 8.8% 1.10 D - 2.00 D, 3% 2.10 D - 3.00 D) and 3.4% have astigmatism > 3.00 D (6).

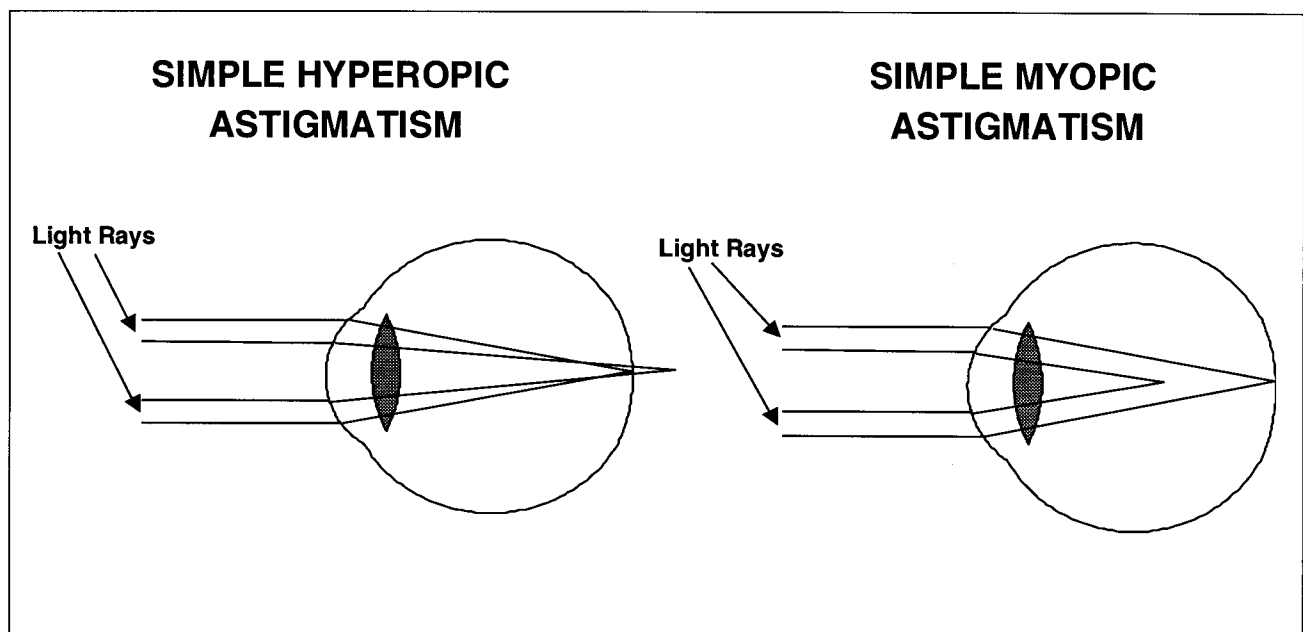


FIGURE 2

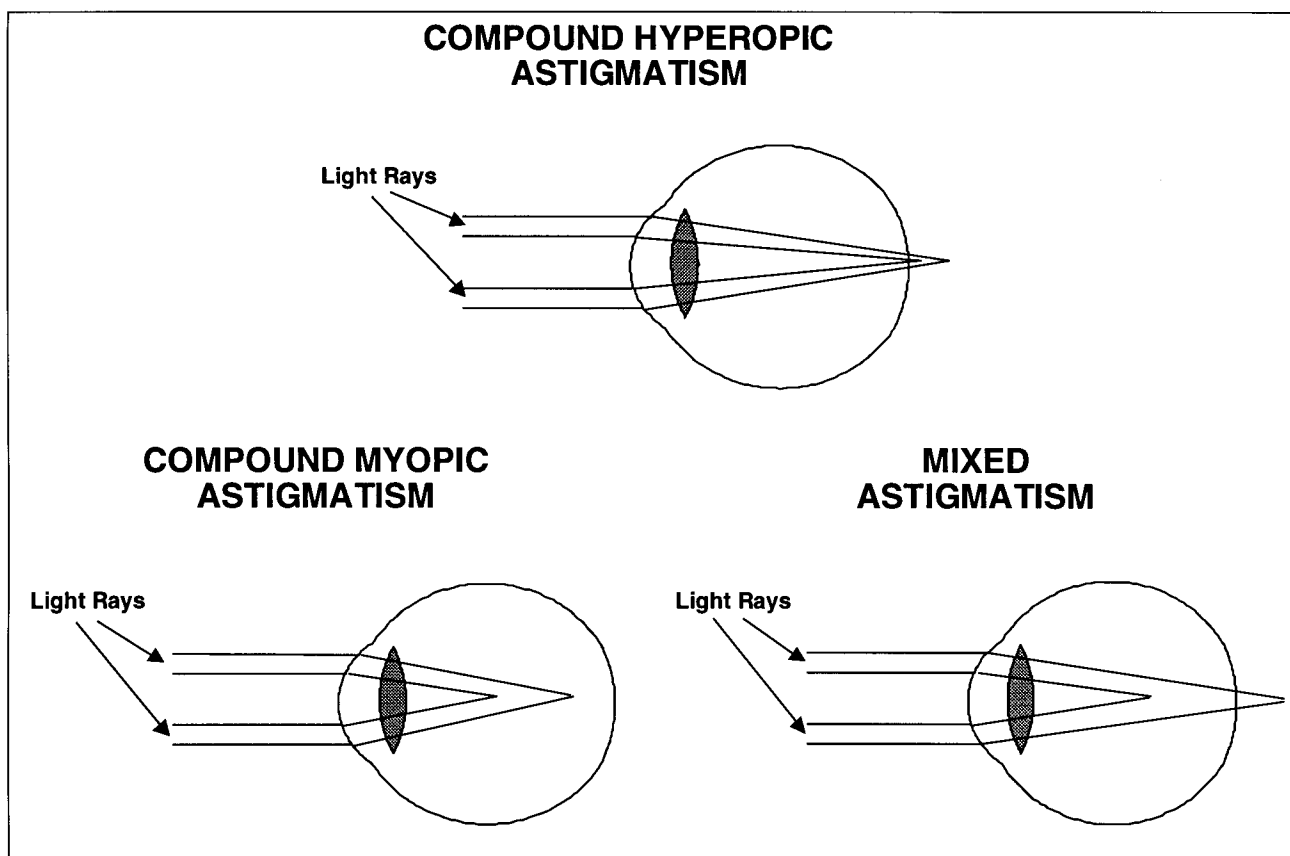


FIGURE 3

II. REFRACTIVE TECHNIQUES

A. NON-SURGICAL TECHNIQUES AND SURGICAL PROCEDURES NOT INVOLVING THE CORNEA

Over the centuries, many techniques have been used with limited success in an attempt to alter or reduce refractive error including nutritional, pharmacological, and visual training (7). The better known of these procedures includes orthokeratology, cycloplegia, clear lens extraction, and scleral reinforcement.

1. **Orthokeratology.** This procedure uses tight-fitting rigid contact lenses that are changed to progressively flatter ones to reduce the curvature of the cornea. Reported complications include induced keratoconus, corneal ulceration, and irregular astigmatism. An advantage of this procedure is its reversibility, as the cornea will return to its original curvature if retainer contact lenses are not worn (8) (see Appendix A).

2. **Cycloplegia.** This procedure involves the daily instillation of a cycloplegic to prevent ciliary spasm, caused by near work, by paralyzing the ciliary muscle in pre-adolescents. Reported complications include photophobia, due to dilated pupils and the inability to predict accurately at what age myopia will develop (8) (see Appendix A).

3. **Clear lens extraction.** This procedure was investigated in the 1980s, but discontinued due to a large number of retinal detachments and other complications that could permanently decrease vision. There has been renewed interest by surgeons using an extracapsular lens extraction procedure with a low power posterior chamber intraocular lens (8) (see Appendix A).

4. **Scleral reinforcement.** With this procedure, the scleral shell is strengthened with a graft to curb the progression of axial elongation. Reported complications include anterior uveitis and retinal detachments (8) (see Appendix A).

B. REFRACTIVE PROCEDURES INVOLVING THE CORNEA

Refractive procedures have concentrated on modifying the anterior surface of the cornea. Of the four physical surfaces responsible for refractive power of the eye, the anterior corneal surface is by far the most important, supplying 44 of the 66 diopters (2/3) that comprise the total refractive power of the eye. These procedures include keratomileusis, keratophakia, epikeratophakia, stromal thermokeratoplasty, and intrastromal corneal ring.

1. **Keratomileusis.** Unique in that it was the first medical procedure where a part of the body was removed, modified, and returned to its original location (9), keratomileusis can correct very high myopia (e.g., 16.0 to 18.0 D) (8). Reported complications of over and under correction (7), corneal perforation during lathing (7,10), irregular astigmatism (4,10,11,12,13), corneal opacities (9), the complexity of the procedure (7), sophisticated equipment (7), cost (12), and unpredictability (13) have resulted in this procedure being discontinued (see Appendix A).

2. **Keratophakia.** A donor corneal tissue is placed in the stromal bed, with the patient's anterior corneal tissue sewn back in place, to steepen the cornea and correct aphakic refractive errors (7). Capable of correcting powers greater than +10.0 D, keratophakia has reported complications with induced astigmatism, loss of best-corrected visual acuity (BCVA), and limited supply of donor corneas (7,14). The development of new and improved intraocular lenses to correct aphakic refractive error contributed to the discontinuance of this procedure (see Appendix A).

3. **Epikeratophakia.** Currently, this is the most widely practiced lamellar refractive keratoplasty technique. Safer and simpler than keratophakia, freeze-dried lenticles are pre-lathed to correct a particular refractive error and sutured into a small epithelial attachment site made in the peripheral cornea, which allows the host epithelium to cover the anterior surface of the donor lens (7). This procedure can be used in the treatment of keratoconus and high myopia (up to -37.0 D) (8). Epikeratophakia has reported complications with neovascularization (7), infections (7), reduction in contrast sensitivity, and difficulty in precise centering of lenticles (15) (see Appendix A).

4. **Stromal thermokeratoplasty.** Initially, a probe placed at 80% depth of the stroma was used to shrink stromal collagen and flatten the cornea (7,16). However, currently a modification of this procedure is undergoing U.S. Food and Drug Administration (FDA) investigational studies using a Holmium YAG laser (Laser Thermokeratoplasty [LTK]) (17). The procedure is used to treat hyperopia and astigmatism. There have been reported complications of corneal changes that include epithelial thinning, recurrent erosions, stromal melting (7), loss of best-corrected acuity (17), regression (17), and unpredictability (17) (see Appendix A).

5. **Intrastromal corneal ring (ICR).** ICR is under FDA investigation. The procedure uses an implanted corneal ring in the mid-peripheral stroma to change corneal curvature (i.e., rings of different thickness are used to induce different corneal changes) (18). There is no direct contact with the central cornea (19), and the ring is easily removed for complete reversibility (18). There have been reported increases in intraocular pressure (IOP) due to corticosteroid use in the post-operative healing phase (18) (see Appendix A).

Of all refractive surgical techniques, the two most widely used are radial keratotomy (RK) and photorefractive keratectomy (PK). These will be discussed in the next two sections.

III. RADIAL KERATOTOMY

A. HISTORICAL AND PROCEDURAL PROCESS

RK was first used on a wide scale by Sato of Japan in 1953. It was considerably refined by Fyodorov of Russia in the early 1970s. Since the late 1970s when it was first introduced in this country, RK has been performed on well over one million Americans. Most recent statistics indicate that RK is increasing in popularity. In 1990, only 50,000 RK operations were performed; in 1992, about 250,000 RK operations were performed; and in 1994, an estimated 300,000 RK procedures were performed on Americans (20). The procedure consists of making incisions radially on the peripheral cornea using a diamond surgical blade, usually to a depth of 90-95% of the central corneal thickness, leaving the central optical zone untouched (see Figure 4). These incisions weaken the peripheral cornea and allow intraocular pressure to push the cornea out, flattening the apex and

RADIAL KERATOTOMY (RK)

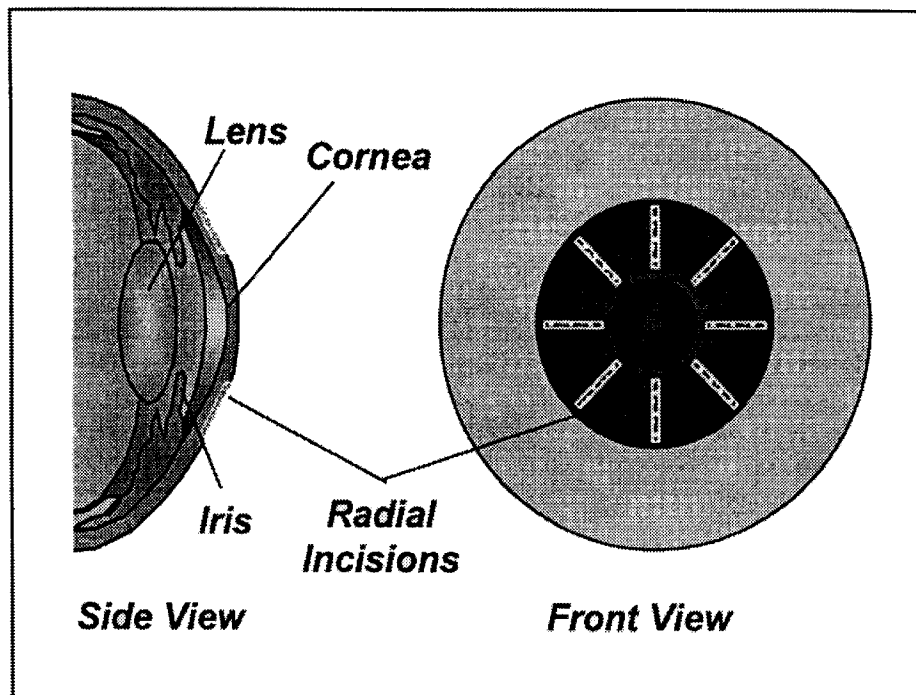


FIGURE 4

reducing its refractive power (8). There are three surgical variables: 1) diameter of the clear zone (smaller zone = greater flattening), 2) number of incisions (4 incisions are equivalent to 75% of the effect achieved with 8 incisions), and 3) depth of incisions (deeper = greater flattening) (21,22). There is a greater effect from RK with age (.75 - 1.00 D/decade of life) (21,22). RK candidates should have stable non-progressive myopia, normal corneas, and be free of systemic disease that might influence corneal healing (21).

B. COMPLICATIONS

1. Anesthesia.

- Optic nerve damage
- Perforation of the globe

(Note: These complications have been reduced with the use of topical anesthesia (8,23)).

2. Operative.

- Corneal perforations (8,24,25)
- Decentered clear zone (21,26,27)
- Incisions across the visual axis
- Monocular diplopia (26,28)

3. Intraocular and eyelid complications.

- Endophthalmitis (8,25)
- Cataract (8,25)
- Traumatic rupture of keratotomy scars (29,30,31,32,33,34)
- Ptosis (25)
- Inferior rectus palsy (25) (Note: This complication has been reduced with the use of topical anesthesia.)
- Retrobulbar hemorrhage (25) (Note: This complication has been reduced with the use of topical anesthesia.)
- Iritis (25)
- Traumatic hyphema (8)
- Epithelial implantation resulting in cysts (8,35)

4. Corneal.

- Bacterial keratitis (36,37,38,39,40,41,42)
- Herpes keratitis (25) (Note: Reactivation is normally due to steroid use.)
- Stromal keratitis (25)
- Fungal keratitis (43)
- Epithelial erosions (8,25)
- Epithelial ingrowth (8)
- Endothelial cell loss (8,44)
- Delayed wound healing (25,27,29,45)

- Excessive limbal scarring (8) (Note: Currently, RK is no longer carried out to the limbus.)
- Neovascularization (36,46) (Note: Normally occurs when incisions are carried out to limbus.)
- Late-onset bacterial corneal ulcers (36,47)
- Central corneal scarring (48)
- Stellate iron deposits (49)

5. Refractive.

- Over correction (i.e., refractive hyperopia) (26,50,51,52,53)
- Under correction (26,54)
- Anisometropia (unequal refractive state for the two eyes) (21,26,54)
- Induced astigmatism (8,26,36)

6. Visual performance.

- Glare (36,55,56,57,58)
- Changes in contrast sensitivity (55,59,60)
- Long-term instability (21,51,61)
- Fluctuating acuity/diurnal variations (56,58,59,62,63,64)
- Ghost images (21,56)
- Loss of optical quality in paracentral and peripheral cornea (55)
- Visual distortion (27)
- Reduced BCVA (21,26,28)
- Diminished night vision (21,55)

C. ADVANTAGES

1. **Rapid recovery.** Usually within a week post-operatively (Note: Second eye can be operated on simultaneously, or within 1 week to 3 months.) (50)

2. Established safety.

- Years of clinical experience (21,65,66)
- Healed incision scars require special ophthalmic instruments to view adequately (8)
- Minimal risk of vision loss from surgical complications (8.3% mild and 0.3% severe) (67)

3. **Procedures for astigmatism.** There are estimates that 63.2% to 73% of the U.S. population has refractive astigmatism (5,6)

4. **Cost.** About \$1,000 per eye (50)

D. DISADVANTAGES

1. Refractive

- Difficulties in contact lens fitting (8)

- Over correction may lead to early presbyopic symptoms (Note: May result in premature need for reading glasses.) (8)
- Irreversible (68)
- Residual refractive error (Note: About 33% of RK patients require corrective lenses either full- or part-time, e.g., reading glasses, night driving.) (69)

2. Limitations

- Limited to correction of myopia and low astigmatism
- Risk of loss of vision increases with the number of incisions, intersecting incisions, and small optical zones (70)

3. Predictability

- Refractive outcome prediction is about ± 2.00 D for 80-90% of eyes (71)
- Enhancement procedures are often required (less effectiveness and predictability with repeated operations) (21)

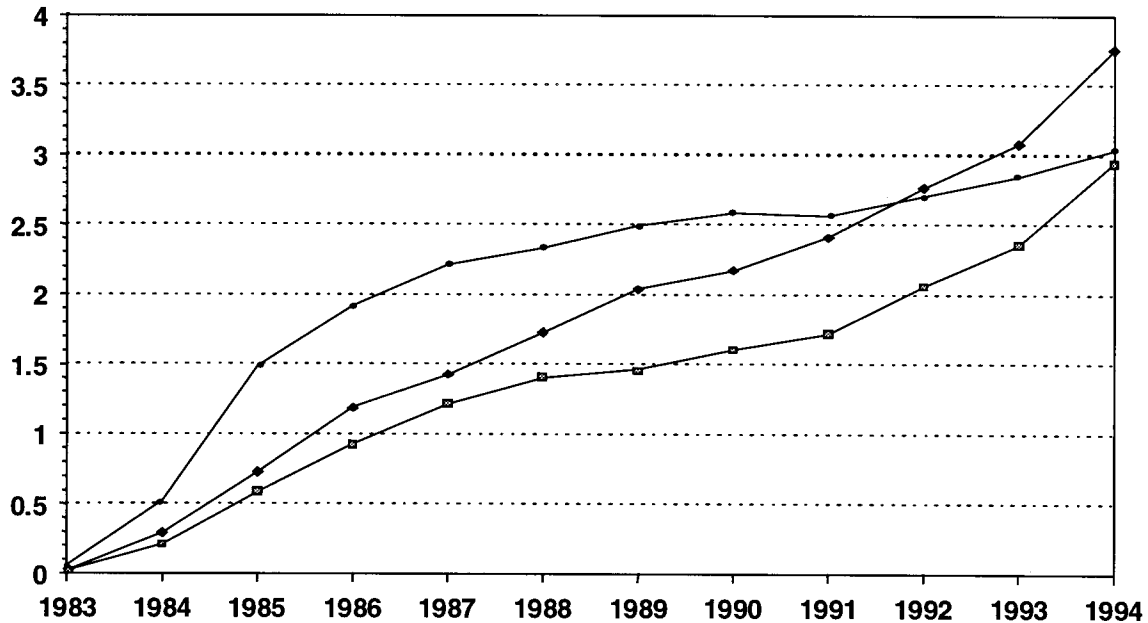
E. CERTIFICATION OF PILOT APPLICANTS WITH RK

1. Certification process.

• **Historical.** Initially, airmen who had RK procedures were allowed to obtain Federal Aviation Administration (FAA) medical certificates through the waiver process. Applicants with RK were required to submit a completed "Report of Eye Evaluation" (FAA Form 8500-7) at least 6 months after their RK procedure when applying for a FAA airman medical certificate. A follow-up second eye evaluation report was also required 6 months later.

• **Present.** Presently, applicants with RK may obtain medical certificates without a waiver by passing the visual acuity standards for the class of medical certificate applied. Airmen with a current medical certificate who have RK performed should discontinue flying until an eye care specialist verifies that their vision is stable and they have been released (72). Verification can be obtained by submitting an eye evaluation report (FAA Form 8500-7) completed by the surgeon who performed the procedure or another eye care specialist familiar with the applicant's ophthalmological history. If no previous eye evaluation report (FAA Form 8500-7) has been submitted by an airman with RK, one is required at the time of certification renewal.

Radial Keratotomy Per 1,000 Civil Airmen



Class I	0.0608	0.5267	1.4829	1.917	2.2145	2.3382	2.4919	2.5893	2.5636	2.7069	2.8508	3.0405
Class II	0.0206	0.2901	0.7279	1.1869	1.4295	1.7262	2.037	2.1758	2.4104	2.7655	3.079	3.7583
Class III	0.0213	0.2111	0.5886	0.9278	1.2166	1.4058	1.4661	1.6012	1.7189	2.0585	2.3528	2.9437

FIGURE 5

2. **Considerations to aviation.** In 1983, RK was assigned its own pathology code (i.e., 130) by the FAA. To expedite the tracking of this condition by the FAA's Aeromedical Certification Division, this code is placed on the medical records of all airmen applicants with RK. Figure 5 presents the prevalence rates (per 1,000 airmen) of RK by class of airman medical certificate held for the period 1983-94. RK has increased in prevalence in each year of the period in the total airman population, and essentially in each year of the period for all classes of certificate holders. RK had the highest prevalence rates in first-class airmen until the end of the period. In 1994, there were over 1,900 civil airmen with RK. While it is expected that airmen who feel threatened by a loss of physical or sensory skills may self-select themselves out of hazardous activities, such as flying, the data suggest that airmen with RK continue to fly and may not perceive a substantial visual problem from any side-effects typically associated with RK.

IV. PHOTOREFRACTIVE KERATECTOMY

A. HISTORICAL AND PROCEDURAL PROCESS

Excimer lasers have been used in ophthalmic and refractive applications since the early 1980s. Laser technology has come a long way since these early applications. Modern lasers are not only considered safe, but they also have the precision capability of literally splitting hairs. The excimer laser's beam can remove 0.25 millimicron-sized portions of corneal tissue with each pulse (3), and the ophthalmic surgeon can actually alter the corneal curvature. The excimer laser, which employs a 193-nanometer (nm) ultraviolet-C light, is emitted as an excited dimer of argon fluoride gas mixture. The high-energy laser light causes an almost instantaneous vaporization of the cornea by direct photochemical disruption of molecular bonds, with theoretically minimal impact on neighboring ocular tissue (73,74,75).

The excimer laser was initially approved by the FDA for phototherapeutic keratectomy (PTK) (76). During PTK the laser is used to perform a superficial

PHOTOREFRACTIVE KERATECTOMY (PRK)

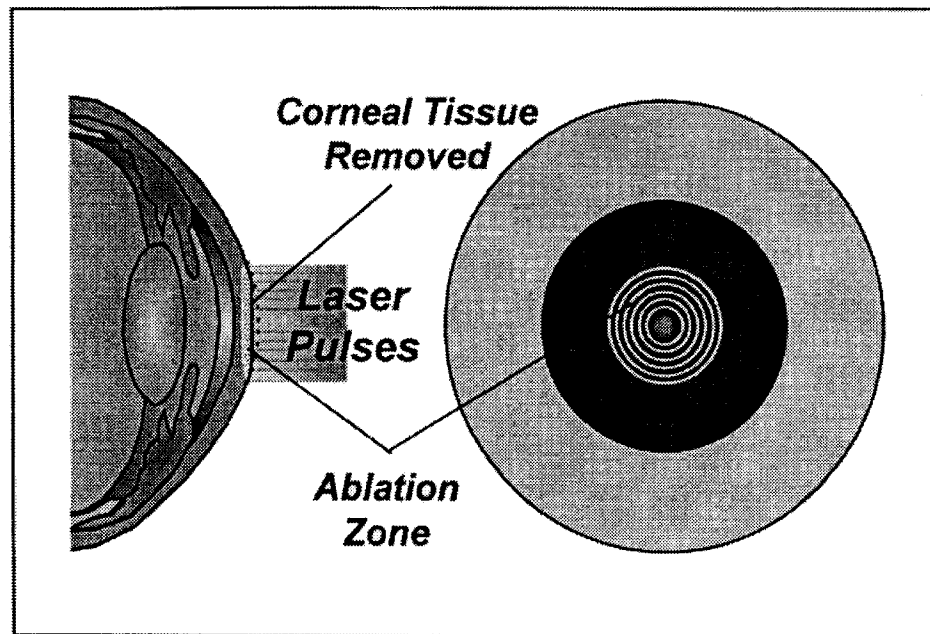


FIGURE 6

keratectomy (smoothing of the corneal surface) remove scars, pterygiums, band keratopathies, and superficial corneal diseases (77,78,79).

Originally for refractive surgery, excimer lasers were used to make semi-radial and linear transverse excisions in the cornea in an attempt to improve traditional diamond-knife RK (80,81,82). However, the laser excisions created wider wounds because tissue was removed (29,83), and provided less control over wound depth (28,84). The cost and sophistication of the laser system precluded its use in this application (85). Consequently, attention was directed toward a wide-area, lamellar stromal excision procedure, termed "photo-refractive keratectomy" (86,87). In PRK, the excimer laser reshapes the anterior curvature of the cornea, essentially "sculpting" the cornea to correct for any refractive error (see Figure 6). After programming the amount of intended refractive change required and baseline eye examination data, a computer-assisted algorithm determines the excimer treatment parameters. Unlike RK, PRK is not surgeon-dependent ("robotic" surgery) (88,89). The excimer laser removes the corneal epithelium (if mechanical debridement of epithelium has not been performed), basement membrane, Bowman's membrane, and portions of the corneal stroma (90).

Since the approval of the Summit laser by the FDA for PRK in October 1995 and the VISX laser in March 1996, lasers previously approved for PTK are upgradable for PRK with the addition of a new software chip (91). Summit and VISX, in an unprecedented move, formed the Pillar Point Partners (PPP) to resolve a lawsuit over ownership of the rights to the excimer laser refraction process (92). As a result, as lasers are upgraded for PRK, a special card is required for the laser device to function. These cards are purchased in batches of 10 for \$250.00 each, so that Summit and VISX can collect a royalty each time the laser is used to perform PRK (93).

Photorefractive keratectomy is an outpatient procedure, which usually requires only topical anesthesia, and is initially painless. The entire procedure, including the manual debridement of the corneal epithelium before initiating the laser, takes about 10 minutes. The actual laser beam exposure is dependent upon the amount of myopia to be treated (average 30 seconds). Immediately after treatment, most surgeons instill an antibiotic combined with a corticosteroid and non-steroidal anti-inflammatory agent. Most surgeons insert a disposable bandage contact lens that is removed when the epithelial defect is healed (2 to 3 days); however, a few still use a firm eye patch for 24 hours (94). Oral analgesics are

prescribed since the eye may become painful 1 to 2 hours post-operatively and may be extremely painful during the first 8 to 12 hours. However, current use of topical non-steroidal anti-inflammatory agents greatly reduces the pain thus requiring fewer analgesics. By the following day, the pain is reduced considerably and the cornea is re-epithelialized in most patients within 48 hours. A topical corticosteroid and antibiotic regimen is normally initiated at the same time as soft contact lens or patch and is continued after their removal (95). Vision is usually considerably improved within 3 to 4 days, and most patients become slightly over corrected for a few weeks before beginning to settle. Correction normally becomes stabilized within 3 to 6 months for low myopia and 6 to 18 months for high myopia (96,97). Regular follow-up visits are necessary for the first year (95).

1. Epithelial removal. Removal of the epithelium before photorefractive keratectomy increases the predictability of results, since its thickness or homogeneity is unknown. Methods used for de-epithelization include mechanical debridement with a blunt spatula or a sharp blade (98); chemical de-epithelization by using topical synthetic anesthetics, cocaine, or alcohol (99); and photoablative de-epithelization with the excimer laser (100). The most commonly used method employs a mechanical debridement with adjunctive chemicals, such as topical anesthetics.

2. Ablation zone diameter. During the clinical evolution of PRK, ablation zone diameters have progressively increased from 3.5-millimeters (mm) to 6.5-mm or more (101). One major reason for this increase was the high incidence of symptomatic halos under night-driving conditions (102,103,104,105,106). A larger optical zone reduces the effect of optical irregularities at the junction of the ablation zone and untreated cornea, which is thought to cause symptomatic halos (107) and may affect objective and subjective post-operative visual outcomes (108). Modern excimer lasers are able to create ablation zone diameters of at least 6-mm for myopia. (Note: The amount of myopic change is directly related to the depth of tissue removed (109) and inversely related to the diameter of the zone. Therefore, deeper ablation and/or smaller zones are required for higher myopia (100).) Patients with larger ablation zones also achieve a more rapid visual recovery with less variation in refractive outcome (110,111). Since patients are not as likely to develop over corrections (more common to smaller ablation zones), they

can return to full activities within a few days (112). Currently studies are underway using larger ablation zones on simultaneous bilateral procedures.

3. Centration of ablation zone. Precise centration of the laser over the entrance pupil is important, as the regularity and centration of the ablated corneal optical zone is imperative to clear, crisp vision (102,113,114,115). Previously, a hand-held suction ring was used during ablation by some surgeons to stabilize the eye (116). Currently, self-fixation by the patient is used during surgery (101). The Summit and VISX lasers only use self-fixation. Centration errors can occur if the eye and laser are not perfectly aligned, there are small involuntary movements by the patient and/or surgeon, the patient loses fixation, or the pupil is irregular (113,117). (Note: Decentration occurs in about 20% of PRK treatments (118).) Self-fixation may be adequate for wide ablation lasers, such as the Summit or VISX lasers. However, techniques that use scanning laser beams and eye-based masks (e.g., the Meditec System) previously required a suction ring-assisted fixation of the eye but are currently using an eye tracking system (82). Decentered or eccentric ablations can generate monocular diplopia, glare, and irregular astigmatism (75,96,105,119,120,121). (Note: A rigid contact lens is normally the only option for correcting this type of astigmatism, so a patient who has previously been unable to wear contact lenses is at greater risk for a decrease in uncorrected and BCVA (96,122,123,124).) (Note: There have been reported losses of two or more lines of BCVA with ablation zones that are significantly eccentric (102).) When both the pupil and ablation diameter are 4.5-mm and the ablation is displaced .5-mm, 14% of the optical zone is outside the ablation area, while a displacement of 1-mm will result in 31% of the optical zone being outside the ablation area, which could induce halos and affect visual function (125,126,127). The halo effect is generally proportional to the amount of correction attempted and is the result of light passing through both the treated and untreated portions of the cornea. In studies of ≤ 5.0 -mm ablation zones, as many as 78% of PRK patients reported halos at night (114,128,129). Larger ablation zones (≥ 6 -mm) have less critical centering requirements when being used for mild to moderate myopia (114,128,130,131,132). However, when larger ablation zones are used for higher refractive corrections, centering is critical due to the steep and deep transition zone (133). (Note: Hyperopic eyes may be more sensitive than myopic eyes

to ablation zone decentration (134).) In general, the visual and refractive outcomes of PRK depend on good centration.

4. Epithelial and stromal changes. The epithelium is normally healed within 4 to 5 days after PRK (95,100), although there have been some reported instances of epithelial wound healing occurring as late as several months after the procedure (135). Studies have shown that normal epithelial barrier function may not return during the first month after ablation, suggesting the importance of minimizing corneal trauma (e.g., eye rubbing, applanation tonometry) (136). When it regenerates, the epithelium is initially thinner than normal. Over time, the epithelium thickens, and may become hyperplastic with greater than normal numbers of cell layers and thickness. This epithelial hyperplasia is common in rabbits (137), non-human primates (138), and humans after PRK (87,139,140), which, if sufficient, may cause a return of myopia (100). This myopic regression is most common in higher myopic patients (128,141,142), and is rarely seen in ablation depths less than 50-microns (μm) (130,143). After PRK, there is little risk of corneal perforation (88,144), corneal rupture (145,146), continued refractive change (88), and abnormal corneal epithelial healing after traumatic abrasion (147). However, corneal ruptures may occur with very deep ablations (31), although the major risk is an increase of corneal opacities (29,148). A smooth corneal surface at 1 to 3 months is no guarantee of a smooth surface at 6 months, as the extent of the deposition of new tissue remains unpredictable (131,149). Recurrent epithelial breakdown and epithelial adhesion problems appear to be extremely rare after PRK (114,144,150).

Bowman's layer, which is partially or completely excised during the PRK procedure, does not regenerate. The clinical significance of the absence of Bowman's layer is uncertain. From a biomechanical perspective, there is evidence that the cornea is not substantially altered (151). However, it is unknown if its absence may predispose certain individuals to a more rapid stromal involvement in developing corneal infections.

Stromal changes may evolve for months or even years after PRK. Recent observations of late regression beyond 18 months and up to 26 months post-PRK have raised clinical concerns that stromal healing may be much slower than previously assumed (152). Initially, the anterior stroma beneath the treatment zone is hypocellular, with fewer than normal anterior stromal keratocytes after 24 hours (99,138). Vision

immediately after surgery is limited, due to the exposed corneal stroma absorbing fluid from the precorneal tear film (153). In about 2 hours, most undamaged keratocytes within 500- μm of the ablation area are activated and begin intense metabolic activity. This activity transforms the keratocytes into fibroblasts (connective tissue cells) that migrate into the treated region, causing the subepithelial thickness of 10- to 15- μm to become hypercellular (87,138). These activated keratocytes synthesize new collagen (protein substance of connective tissue) and extracellular matrix (contains type III collagen [anchoring fibrils], type IV collagen [basement membrane], type VII collagen and newly produced keratan sulfate), all of which may contribute to the corneal haze observed post-operatively (154).

In patients with delayed epithelial healing, the cornea is at risk for developing infectious keratitis (95), ulceration, and greater post-operative corneal haze (100,121). Conditions reported to delay healing in PRK patients include: 1) keratoconjunctivitis sicca (tear deficiency resulting in dry eyes), prompting most specialists to recommend the tear film be assessed and all dry-eye conditions be treated pre- and post-operatively (100); 2) epithelial toxicity, which may be related to topical anesthetic agents applied before epithelial removal, topical anti-inflammatory agents, and prophylactic antibiotic therapy (100); 3) reduced oxygen availability to the corneal epithelium (i.e., bandage therapeutic soft contact lenses fit excessively tight) (100); and 4) an enlarged corneal epithelium debrided area (100).

5. Corneal endothelial changes. Endothelial damage, documented with very deep (about 90% depth) linear excimer laser excisions, is probably due to acoustic or shock waves from the laser (155,156). In rabbits and non-human primates, the corneal endothelial cells appear to be unaffected after wide area superficial corneal ablations from PRK (86,138,157,158,159,160). No significant change in human endothelium cell density and morphology has been found up to 12 months after PRK (correction between -2.50 to -17.0 D) (44).

B. SELECTION CRITERIA

1. Post-operative vision.

- Potential patients should be aware that PRK is an elective procedure and there are alternatives for refractive correction (eyeglasses, contact lenses, orthokeratology, and other refractive surgery) (161).

- It is recommended that perfectionist patients with high expectations for perfect post-operative unaided vision be excluded (95).

2. Sex. The only gender-based exclusion is pregnant women (95).

3. Age

- Patients should be ≥ 18 years of age with the VISX Laser and ≥ 21 years of age with the Summit Laser. (Note: The difference in the approved age for PRK by the FDA was based on investigational data supplied by laser manufacturers.)

- Near presbyopic patients should be warned that glasses may be required for near vision after surgery (95).

- There is a trend to greater over correction (induced hyperopia) in older patients for the first 6 months after surgery (162,163,164,165).

4. Ocular/systemic disease

- A complete eye examination before surgery is required to identify contraindications such as:

- a) Collagen vascular disease (e.g., corneal ulceration or melting) (146,166)

- b) A history of ocular disease or an abnormality (e.g., dry eye, keratoconus, glaucoma or glaucoma suspects, incipient cataracts, herpes simplex keratitis, amblyopia) (95,167)

- c) Systemic disorders that may potentially affect wound healing (e.g., diabetes, rheumatoid arthritis, systemic lupus erythematosus, lagophthalmos, polyarteritis nodosa) (146, 162,166)

- d) A history of steroid intraocular pressure response (146,166)

5. Amount of myopia

- Predictability of refractive outcome is inversely related to the degree of myopia (relatively good ≤ -4.00 D, less predictable > -6.00 D) (95,168,169, 170). However, it has been reported that even low myopic patients may achieve only partial refractive correction and may even experience complete myopic regression (171,172).

- Variability in corneal wound healing and the incidence of complications (e.g., glare, over correction, scarring, regression) increases with greater amounts of myopia (95,97,120,128,142,144,164,165,170,171, 172,173,174,175,176).

6. Astigmatism. The FDA recommendation that only patients be treated with refractive astigmatism of ≤ 1.00 D with the VISX Laser and ≤ 1.50 D with the Summit Laser was based on the investigational data originally submitted by each laser manufacturer (95,163). In July 1997, the FDA approved the VISX Excimer Laser System to perform moderate levels (≤ 4 D) of astigmatic PRK. Summit currently has investigational data before the FDA Ophthalmic Devices Advisory Panel to allow their laser to treat moderate levels of astigmatism.

7. Binocularity

- Current FDA guidelines recommend a minimum of 3 months between treatments while others recommend longer periods of up to 6 months for higher myopia. However, some surgeons are currently doing simultaneous bilateral surgery.

- Time between surgeries allows for a stabilization of refraction and manifestation of complications in the first eye (95), but may greatly affect binocularity. The healing response of the first eye may be used to modify treatment in the second eye.

8. Contact lens wear

- Contact lens wearers are good PRK candidates, since they can wear a contact lens in the untreated eye to achieve comfortable binocular vision during the interval between treatments.

- Patients with fluctuating refraction due to corneal distortion from contact lens wear should be excluded until stabilized (95).

- Unsuccessful contact lens patients may have underlying lid disease and dry eyes that could interfere with post-surgical healing if untreated (163).

9. Occupation

- Caution should be exercised when considering treating individuals with demanding occupational vision requirements (e.g., pilots, truck drivers) (95), since early research protocols excluded such patients (171,172,176).

- Refractive surgery is disqualifying for entry into the U.S. military, but may be performed on active duty personnel. It is disqualifying for all members on flight status and some special schools in the armed forces (177).

- Local police or fire departments may reject an applicant who has had refractive surgery (95).

10. Pupil size

- Patients with large pupils are likely to experience a “halo effect” around lights, especially at night (171,172,176). Patients undergoing corrections greater than -4.00 D with pupil diameters larger than 6-mm in subdued lighting should be counseled concerning this complication (95).

- Younger patients, who normally have larger pupils than older persons, may experience significant halo problems while driving at night.

- Current FDA-approved lasers provide ablation zones diameters of 6-mm, which should minimize halo effects (95).

C. CLINICAL STUDIES

1. Stability

- The post-operative time required for a stable refraction may vary due to the age of the patient, amount of attempted myopic correction, and type of laser used. Stable refractive correction has been reported at 3 (173), 6 (171,178,179), and 12 months (99). A study of 146 PRK patients (193 eyes) followed for 2 years reported that the stability between the 1- and 2-year visits was excellent, except in the subgroup that had pre-operative refraction of > -9.00 D (142).

- PRK retreatment rates range from 0.64-9.1% (139,168,141). Retreatment is used to correct corneal scarring, under correction of higher refractive error (180), myopic regression, corneal haze, and topographic irregularities (181). Retreatment enhances the results of PRK, although it is less accurate than the initial PRK procedure (182). A higher retreatment rate was observed after astigmatic correction than after spherical corrections (182).

2. Efficacy

- The efficacy after PRK is generally reported as:
 - a) The percentage of eyes that achieve a post-operative refraction within ± 1.00 D of emmetropia.

- b) The percentage of eyes that achieve 20/40 or better uncorrected distant visual acuity.

Such data may be helpful in assessing efficacy and predictability of a procedure, but they are not absolute measures of “refractive success.” Patients with residual refractive errors achieving 20/30 or 20/40 acuity may continue to report they need a vision correction for a substantial part of the day. (Note: The international

standard for normal vision is 20/20 ± 1 line of Snellen visual acuity. Therefore, many surgeons are now suggesting that uncorrected acuity after refractive surgery should meet this criterion to be successful.) Patients with high myopia may consider a refractive procedure to be successful even with substantial residual myopia.

- Due to the sometimes extended corneal healing with PRK, it is believed that clinical reports of visual performance at < 12 months have little clinical relevance. Therefore, we have focused on reporting data from those studies with post-operative data ≥ 12 months.

- At 12 months, post-operative uncorrected vision was 20/20 or better in 58-75% of eyes (164,183), 20/25 or better in 74% of eyes (117), and 20/40 or better in 85-95% of eyes (117,128,164,173, 174,178,184,185,186,187).

- At 12 months, post-operative refractive error was within $\pm .50$ D of emmetropia in 48% (183) and within ± 1.00 D of emmetropia in 70-98% of myopes of less than -3.00 D (102,117,128,164, 173,174). For myopes of -3.00 to -6.00 D, 60-92% were within ± 1.00 D of emmetropia at 12 months (96,121,168,169, 178,186,188,189).

- At ≥ 15 months, post-operative uncorrected vision was 20/20 or better in 66% of eyes (190), 20/30 or better in 81.5% of eyes (97,191), and 20/40 or better in 71-100% of eyes (97,173,174,189).

- At ≥ 15 months, 71.7% were within $\pm .50$ D of emmetropia (97) and 71-92% were corrected to within ± 1.00 D of emmetropia (97,173,189,190,191).

- At 2 years, post-operative vision of 20/20 or better was reported in 58% of eyes and 20/40 or better in 94% of eyes (161).

- At 3 years, a study of 117 eyes with PRK reported post-operative uncorrected vision of 20/40 in 83% of eyes, 20/20 in 37% of eyes, and 88% of eyes were corrected to ± 1.00 D of emmetropia (192).

- At this time, the clinical stability and long-term side-effects are unknown.

3. Safety

- Loss of BCVA is a major safety issue of the PRK procedure. Clinically significant visual loss is generally reported as the loss of 2 or more lines of BCVA (193,194). Data from previous FDA-supervised refractive surgery trials report that 1-3% of patients undergoing PRK lost 2 or more lines of Snellen acuity (195), while other more recent FDA data indicate that 42 of 480 eyes (8.8%) declined by more than 1 line from pre-

operative conditions (161). Factors related to the etiology of this problem include:

a) Post-operative haze: Present in most patients at 2 to 3 months (196,197), it disappears in most eyes at 1 year (178). One study reported that at 12 months 30% of eyes had a trace and 4% had mild to moderate haze (186). Another study reported 85% of eyes had more than a trace of haze at 24 months (198,199). Variables that influence the severity of corneal haze include: size of ablation zone (75,200) (greater haze with smaller zones (135)), deeper ablation depths (148,200), single ablation zone procedures (200), male gender (135), higher myopic correction (128,135,171, 196, 201,202,203, 204,205), shorter re-epithelialization time (148), fibroblast proliferation (206), differential healing response (103,207,208), myopic regression (128,171,204), and dry eye (tear fluid components are known to stimulate corneal healing) (209). More significant haze with the absence of steroid use or discontinuation of corticosteroids to modulate the haze response has been reported (135,196). However, even with the use of steroids, corneal haze was reported present in some cases at 6 months (179).

b) Irregular astigmatism: Astigmatism induced by PRK is relatively uncommon compared to other refractive procedures (210). It can occur with decentered ablation zones and/or asymmetric healing (100). In one study, > 0.75 D of induced cylinder was observed in 2.5% of cases at 1 year post-operatively but declined to 0.0% at 2 years after surgery (142).

c) Corneal scarring: A leading cause for loss of visual acuity (29,102,105,115,118,125, 174,176, 211,212), corneal scarring reduces optical clarity (213) and produces glare (104,126,202). It is more prevalent in PRK patients with corrections > 4.00 D (118, 125,171).

d) The accuracy of refractive correction is diminished on traumatized corneas (214) and as larger corrections are attempted (173). Over corrections increase in multi-zone ablation procedures (215).

e) Approximately 15% of PRK patients may experience over correction, and resulting near vision disturbances or increased corneal haze and rapid myopic regression (216).

- **Decrease in contrast sensitivity**

a) Loss of contrast sensitivity may not be detectable under conditions typically used for measuring Snellen visual acuity (100). Sher et al. (120), using

the Vistech MCT-8000 and Pelli-Robson chart, found no significant difference in contrast sensitivity function (CSF) at 3 months after PRK. However, others have found reduction in CSF during exams at the 12-month post-operative period (175,189,217). Ambrosio et al. (218), using stationary or temporally modulated sinusoidal gratings, found post-PRK patients with low myopia to have a reduction in both static and dynamic contrast sensitivity at 1 month. At 6 months, static sensitivity had recovered, but there was a persistent loss of dynamic sensitivity.

b) Reduction in contrast sensitivity seems proportional to the amount of corneal haze (109,203). However, post-operative reduction in contrast sensitivity and glare may occur in eyes with "crystal clear" corneas, suggesting that visual loss and "halo effect" are not attributable to reduced corneal clarity alone. These effects may stem from an apical corneal surface that differs substantially from sphericity (124,219), since the main retinal image is accompanied by a "ghost" image.

c) It has been speculated that larger ablation zones (minimum of 6-mm) may lessen the amount of induced CSF loss (114,128, 130,131,132). However, a recent study reported that even with ablation zones of 6-mm, there was a loss of daytime contrast sensitivity with peripheral glare (220).

- **Ultraviolet-C (UV) exposure**

The long-term effects of UV-C exposure from the excimer laser are unknown at this time. Such exposure has been reportedly linked to:

- a) Formation of free radial byproducts (221,222)
- b) Mutagenic and cataractogenic effects (221)
- c) Premature expression of certain age-related conditions (217)
- d) Central corneal thinning that may result in keratoconus type anomalies (223)
- e) Corneal graft rejection (224)
- f) Cataracts (102)

4. Side-effects

- **Thermal damage**

a) Although the excimer laser photoablation process is non-thermal, temperature changes on the corneal surface occur as molecular bonds break (130). Berns et al. (84), using a thermal camera, showed an average increase in corneal temperature of 20°C. With pulsed laser energy, higher temperature spikes occur on

the surface. While these spikes may not be sufficient to denature the surface corneal collagen, they may affect keratocyte activation and corneal wound healing (130), which also may influence the severity of corneal haze (225). Current studies investigating ways to reduce the amount of post-operative haze use irrigation and reduction of the excimer laser pulse width to cool the cornea (130,225).

5. Specific complications.

• Healing responses

a) Normal responders, or Type I (85-95%), demonstrate a slight hyperopic over correction at 1 month with gradual regression toward emmetropia (normally within 6 months). Approximately 26.5% have a trace of haze and 7.1% have moderate to marked haze at 6 months (216,226).

b) Inadequate responders, or Type II (3-11%), show a clear cornea and marked hyperopic over correction (> 1.00 D) at 1 month with minimal regression at 6 months. About 30.8% have a trace of haze at 6 months (216,226).

c) Aggressive responders, or Type III (1-4%), display an early over correction with rapid myopic regression. Approximately 20% have a trace of haze and 80% have moderate to marked haze at 6 months (216,226). Type III healing response has been linked to such variables as age, race, and eye color (227). Aggressive healing response can occur at any point within the first 2 years after PRK, indicating corneal remodeling is ongoing (226,228). Late haze marks the onset of Type III response, which can produce irregular astigmatism and visual disturbances (226,228). Type III response can occur after some sort of corneal insult or irritation (e.g., corneal abrasion, UV keratitis, dryness, contact lens wear, eye rubbing, acute or allergic conjunctivitis, and topical eye medications) in patients who have undergone metabolic stress (pregnancy, lifestyle change (227)) or in patients who have PRK after having had previous refractive surgery (227). Eye doctors now recommend that contact lenses be discontinued for post-PRK correction until corneal healing is complete (about 1 year) and anesthetics should be avoided (such as for applanation tonometry) (226).

• Post-surgical corneal opacities

a) Partial loss of corneal clarity is common after PRK (142,229,230,231,232,233). The rate and severity of opacities are proportional to the attempted correction (29,135,139,148,178, 202). Corneal

scarring, sufficient to reduce visual acuity by 2 or more lines, occurs in about 1% of PRK patients (139).

b) Corneal haze is time-dependent. Initially clear, corneal haze is usually maximal between 3 and 6 months (115,120,135,162,172), with progressive clearing normally at 1 year post-operatively (120,162).

c) The incidence of patients with a corneal opacity severe enough to warrant reoperation is 0.81-3.7% (102,139,171,173). There is currently no method for predicting which patients might develop an exaggerated wound-healing response resulting in corneal opacification.

d) In more than 80% of PRK eyes, a central round intraepithelial iron deposit is visible 1 year after surgery (102,234). This deposit has minimal effect on visual function. In otherwise clear corneas, the central iron spot is the only clinical sign of a previous PRK. However, the definitive tool for following PRK patients through the healing process is a corneal topography system, which is expensive and not available in many ophthalmic practices.

• Glare/Halos

a) Mild to moderate night glare sensitivity and halos have been reported in as many as 27% of PRK patients (103,106), the severity of which often prevents driving at night during the first few months after treatment (201). At 1 year, 10% of patients reported persisting effect, and 50% of those reported it severe enough to interfere with night driving (141,176). In one study, 10% of PRK patients declined to have the fellow eye treated because of disturbances in night vision and associated symptoms of glare (217). This phenomenon is difficult to measure, since there is no known mechanism to define a patient's tolerance to glare (106,235).

b) Of PRK patients, approximately 60% reported reduced quality of vision in dim lights (121,141,178), 38% reduced quality of vision in artificial light compared to daylight (141,178), and 14% fluctuation of vision (178).

• Pain

a) Pain can be moderate to severe (130,236) or up to significantly intense, 10 to 24 hours after surgery (75,237). In most patients, pain is normally gone at 3 days post-operatively (175,237).

b) Pain may be more significant in females, which could be due to gender differences in epithelial healing (238).

c) Pain has been a major reason patients chose to delay PRK or have RK to correct the second eye (239). Individual perception of pain is highly variable, and an objective analysis of pain may be complicated by exposure to light, patching or non-patching, and proximity of surgery to sleep periods (240).

- **Corneal ulceration**

a) Corneal ulcerations have been reported in the early post-operative PRK period (168,210) which may be related to the use of disposable soft contact lenses to bandage the ablated cornea immediately after surgery.

- **Corneal sensitivity**

a) Excimer laser PRK may sever corneal nerve endings, resulting in transient corneal hyposensitivity. Reduced corneal sensitivity can alter the corneal metabolic process (114). After PRK decreased central corneal sensitivity has been measured, while the peripheral cornea (outside the ablation zone) remained unaffected (241).

b) The corneal sensitivity recovery time for low to moderate myopic patients is normally 4 to 6 weeks (242). However, at 3 months, 86% of highly myopic patients reportedly still demonstrated reduced sensitivity (100).

- **Sterile corneal infiltrates**

a) Sterile infiltrates normally develop during the first several days after surgery (120).

b) Treatment with topical non-steroidal anti-inflammatory agents and the use of therapeutic soft contact lens may be predisposing factors for sterile infiltrates. Lesions will typically disappear after 2 weeks of corticosteroid treatment (100,243).

- **Regression**

a) Seldom reported after 3 months in low to moderate myopia (114), myopic regression occurs more frequently in higher corrections (118, 128,146,153, 171,196,201,244). Regression is associated with the discontinued use of topical steroids (113), epithelial hyperplasia, and redeposition of new collagen (196). There also has been some thought that regression might be caused by the slow distortion of existing tissue rather than the growth of new tissue (206). There have been reports that it may be exacerbated by exposure to UV radiation (e.g., bright sunlight, and arc welding) after treatment (95,245). It has been recommended that all PRK

patients wear eye protection from UV (e.g., sunglasses that block 100% UV rays, welding goggles) during post-operative recovery (245).

b) Myopic regression may be influenced by age, corneal steepness and hydration (88), and wound healing response (246). It has occurred, in some rare cases, up to 18 months after surgery (204,247).

c) Successful outcome of the first eye does not guarantee the same result for second eye, as eyes may heal differently (95).

d) Regression is a major cause of dissatisfaction after PRK (171,172,176). Reoperation may be required; however, an extended waiting period of 6 to 12 months is recommended (122).

- **Over/Under correction**

a) Normally, over correction and subsequent regression occurs during the first 3 months after surgery (117,125,165,171), which may interfere with a patient's ability to work (202). Refraction may remain unstable for up to 1 year (153,164, 213,248). Over corrections (196) also occur more frequently in patients 40 years or older (164), steroid responders (164), multi-zone PRK procedures (215), and with the use of non-steroidal anti-inflammatory agents and bandage contact lenses (165).

b) There is increased risk of under correction with higher refractive errors (102,105,148,173, 213,249).

c) The reoperation (enhancement) rate with PRK has been reported to be 5-8% (compared to RK at 10-40%) (176,250).

- **Corticosteroids**

a) Corticosteroid treatment has been used to treat post-operative pain, photophobia (117), corneal haze (114,251), and to reduce myopic regression after PRK (251).

b) The ocular response to steroids suggests ongoing corneal healing (176). At 1 year post-operative, there is reportedly no statistical difference between PRK patients with < 6.00 D of myopia who received corticosteroids and those who did not (171,252). However, Seiler et al. (101) reported that discontinuation of corticosteroids caused an increase in corneal haze (145) and a myopic shift of 0.50 to 1.00 D within days, combined with a subsequent drift of 0.25 to 0.50 D over 1 month (103). (Note: Emmetropia is normally restored by reinitiating corticosteroids within the first weeks after myopic regression (204).) In patients who develop

severe haze and regression at 1 year post-operatively, noncompliance with steroid use was found to be the cause in approximately 50% of these cases (114,162).

c) Complications from corticosteroids include: foreign body/dry eye sensation (178,191,209), tear film alteration (178), herpetic keratitis recurrence (253), anisocoria, loss of accommodation (254), ocular hypertension (191), and cataract formation from long-term usage (227).

d) Elevated intraocular pressure is the major complication from using topical corticosteroids, affecting 10-20% of PRK patients who use them (105,139,170,186,255). This percentage may be as high as 50% in high myopes (102). Usually, intraocular pressure is reduced with discontinuation of corticosteroids, but some (about 1.7% (75)) require therapy for ocular hypertension over a limited period of time (100). There have been reports (up to 22%) of induced open angle glaucoma due to corticosteroid use after PRK (103,171,174).

e) At this time, there is no consensus on the benefits of pre- and post-operative corticosteroid therapy on the outcome of PRK (95).

- **Non-steroidal anti-inflammatory agents**

a) These agents have been used to decrease post-operative pain after PRK. Studies have shown that those treated with non-steroidal anti-inflammatory agents had less initial and overall pain, photophobia, burning/stinging, and require fewer oral narcotics (243).

b) Since soft contact lenses are commonly used with these agents (243), care must be taken to reduce the risk of possible lens complications (e.g., tight lens syndrome, infectious keratitis (243)).

c) Currently, there is ongoing research on the use of non-steroidal anti-inflammatory agents that retard fibroblast activity to control the post-operative corneal cellular response (100,256). However, some of these drugs have been associated with inhibition of epithelial wound healing (256).

- **Diurnal fluctuation in vision**

a) A common complication of RK, diurnal fluctuation in vision, has not been reported in most PRK studies (144,176).

b) One study did report fluctuations of 14% of PRK patients at 6 months and 4% at 12 months (178). In contrast to post-RK eyes, which tend to show increasing myopia, the post-PRK refraction shifted toward hyperopia during the day (158).

- **Central islands**

a) Central islands are topographic non-uniformities of the cornea following PRK. Analysis reveals a region of higher refractive power, compared to the flattened central cornea. With a corneal topography system, the flat cornea is projected in blue while the steeper cornea is projected in green, giving an "island in the sea" picture.

b) Central islands have been reported with all brands of excimer lasers (75) and incidence varies, depending on the defining criteria and post-operative time. Rates as high as 60% of patients (117,186,257) have been reported in the first few months after surgery, decreasing to about 3% at 6 months (117).

c) Central islands are reportedly more prevalent with ablations > 5-mm in diameter (with each 0.5-mm increase in diameter, there is a > 2X increase in the odds ratio for central islands) and eyes treated without nitrogen gas-blowing (16-88%) (258). (Note: Nitrogen gas-blowing is primarily used with the VISX laser.)

d) Symptoms of central islands include: under correction, reduced BCVA (257,259,260), diplopia (259), glare (259), and distortion (261).

e) The etiology of central islands includes: 1) shock wave formation (262,263), 2) ejection of a plume gaseous and particulate debris interfering with the passage of succeeding laser pulses (264), 3) optical problems within the laser delivery system or a variation in laser beam homogeneity leading to less ablation of tissue centrally (100,265), 4) differential hydration of the corneal tissue during the PRK procedure (100), 5) differential corneal healing process (100), and 6) incomplete corneal de-epithelialization resulting in raised areas on the stroma (98).

f) Most central islands resolve spontaneously; however, corneal contours may continue to change from 1 to 6 months (257). When islands persist, retreatment with a second laser ablation may be required (261). (Note: The optimal time for reablation should be performed only after the patient demonstrates a stable refraction and corneal topography (215,266).)

g) New software has been developed in an attempt to decrease the occurrence of central islands with increasing ablation zones (100). Multi-zone and multi-pass ablations and aspheric algorithms have been proposed to make a smoother corneal surface (267,268,269). Their value has yet to be established in clinical trials.

- **Subretinal hemorrhages**

a) There have been reports of spontaneous retinal hemorrhages in pathologic myopes (Fuchs' spots), resulting in severe post-operatively vision loss (100). Whether the incidence of these subretinal hemorrhages is increased with PRK is unknown. During PRK, mechanical stress waves travel through the eye and may irritate or disrupt the fragile subretinal vessels (100).

- **Other complications**

a) There have been reports of mild blepharoptosis (drooping upper eyelid) in some PRK patients, which may be related to use of lid speculum during the procedure. These cases spontaneously resolved in 3 months (100).

b) About 5% of PRK patients have anisocoria (pupils of unequal diameter) for up to 12 months after surgery (100).

c) Patients who subsequently develop a cataract following PRK may have difficulty in getting the correct power for intraocular lens implants (270). Additionally, patients who develop myopic regression are at increased risk for measurement errors in their intraocular lenses (270).

D. FUTURE DEVELOPMENTS

In theory, PRK corrections of up to 20.0 D are possible (201,271,272) (compared to 8.00 D for RK) (29). The impact of epithelial and stromal wound healing on corneal clarity define the upper achievable refractive limits (272). Meanwhile, there are several new developments that may further improve laser refractive surgery techniques.

Studies are being conducted using multi-zone/multi-pass procedures for high myopia (117,215,269,273,274,275,276). The multi-zone techniques are used to limit ablation depth, while multi-pass techniques reportedly smooth the ablated surface (276).

An erodible mask (184,277,278,279,280) is being developed that allows the excimer laser to correct astigmatism (134,171,180,278,281,282,283,284,285) and hyperopia (124,180). The mask is composed of polymethyl methacrylate, which is the material used in rigid (non-gas permeable) contact lenses, and a quartz substrate. The mask absorbs the laser light and is eroded (vaporized) in the process, while also transmitting undisturbed portions of the UV-C light. The surgeon uses these specifically contoured masks to control where and how the laser energy is applied to the cornea, allowing selectively contoured corneal surfaces. How-

ever, use of the erodible mask and lower ablation rate increases the total time needed for the PRK procedure, thus increasing the risk of an imperfect treatment due to decentrations and micromovements (286). Besides these erodible masks, iris (247,287) slit (288,289), and oval apertures (188) of different sizes may be used with the excimer laser to create toric ablations to correct astigmatism.

Currently, there are ongoing studies on the use of PRK to correct residual myopia after refractive surgery (290,291,292,293,294,295,296,297), to correct irregular astigmatism (resulting from previous refractive surgery, pterygium removal, penetrating keratoplasty, cataract surgery) (298,299,300), and to treat keratoconus (301).

The excimer laser used with laser-assisted in situ keratomileusis (LASIK) has great promise for correcting higher myopia (11,302,303,304,305,306,307). The LASIK procedure can be performed with the laser used to perform PRK. LASIK removes tissue from the inner corneal layers, rather than from the exposed epithelial surface (see Figure 7). A specially designed knife blade (microkeratome) slices a thin, horizontal flap (100- to 200- μ m in depth) (308) off the top of the cornea leaving it connected by a small hinge of tissue. The flap is folded aside and the excimer laser is used to remove tissue from the corneal stroma. The flap is then replaced (termed "flap and zap"). LASIK has significantly less scarring and regression, since Bowman's layer of the cornea is not ablated (308,309,310). Post-operative patients typically are more comfortable, stabilize faster, do not require extended use of topical steroids, and have fewer long-term complications and side effects, compared with other types of refractive surgeries (308,310,311,312). LASIK appears also to be effective in the treatment of astigmatism.

The major complaint of LASIK is foreign bodies in the corneal interface and epithelium of the corneal flap. Operative risks include: 1) ocular perforation, 2) dislodged or detached corneal flap (313) (A study of patients undergoing repeat procedures at 6 months reported that, by removing the epithelium at the incision, the corneal flap could be folded back and another ablation performed. This suggests that even at 6 months post-operative the flap has not yet adhered to the stromal bed. (313)), 3) poorly aligned or positioned flap resulting in irregular astigmatism (about 1%), 4) epithelial ingrowth (2%), 5) foreign bodies in the stromal bed, 6) slower healing rate (314)), and 7) microkeratome-induced subconjunctival hemorrhages (310).

LASER-ASSISTED IN SITU KERATOMILEUSIS (LASIK)

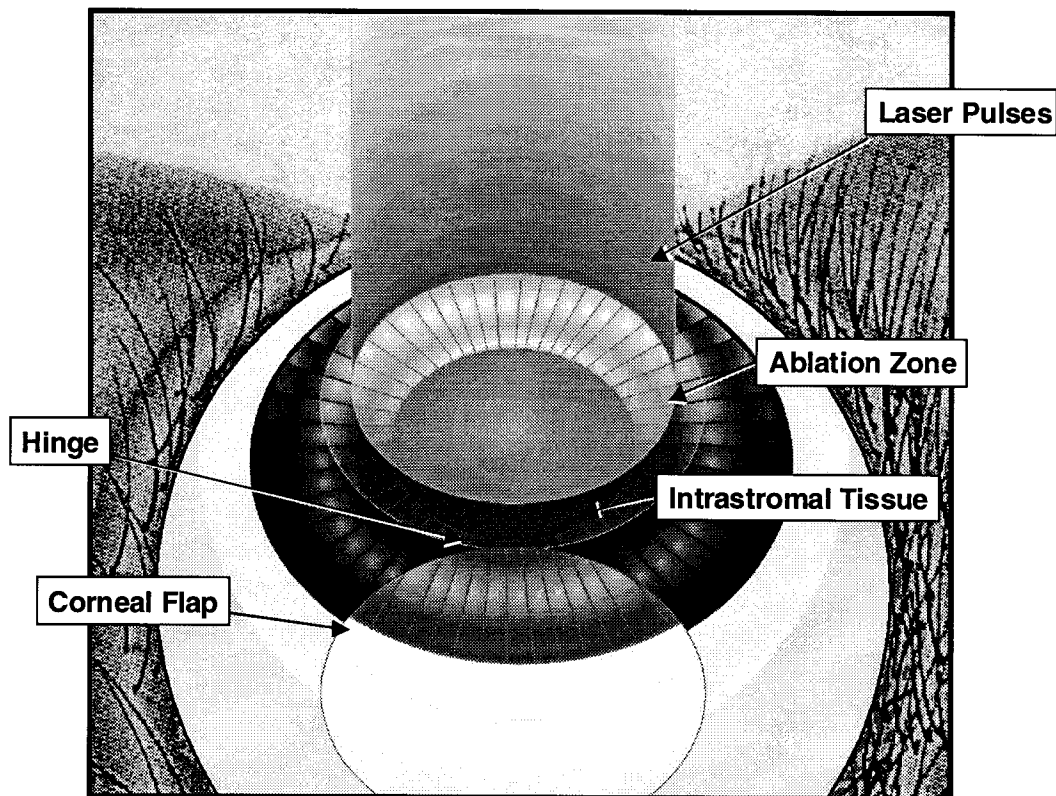


FIGURE 7

Recently, the Ophthalmic Devices Panel of the FDA's Medical Devices Advisory Committee recommended the agency grant its first approval for the marketing of LASIK for the correction of myopia from 1D to 15 D (315). Currently, surgeons can recommend and perform LASIK on a patient, if in their medical judgment, it is the best procedure to correct their particular refractive error. However, surgeons cannot actively market or promote the LASIK procedure (316). It is anticipated that more surgeons will be performing LASIK in the future as they obtain the extensive surgical skill.

Second generation excimer lasers are being used in foreign countries and include delivery methods that allow scanning ablation, multi-zone/multi-pass techniques, and increased beam diameters. Scanning lasers may produce more uniform ablations with fewer central islands. Multi-zone/multi-pass laser techniques are being used that may result in better healing and faster recovery. There have been more reported complications (e.g., halos) associated with smaller zones, so many foreign countries are now using a 6.5-mm ablation zone. Second generation lasers in U.S. clinical trials

include head and eye auto tracking, which may improve predictability. Solid-state, third generation lasers may allow ablations at 213-nm, rather than 193-nm used by the excimer laser (317).

V. AEROMEDICAL ISSUES

A. CERTIFICATION OF PILOT APPLICANTS

Airmen with PRK have applied for and received FAA medical certificates prior to the October 1995 FDA approval of the Summit excimer laser. Patients went to foreign countries, primarily Canada and Mexico, for this procedure. Before FDA approval, it was estimated that about 60% of the PRK patients in Canadian clinics were U.S. citizens.

- Applicants with PRK and other refractive surgical procedures are being medically certified without a waiver.

- PRK applicants are assigned a FAA-specific eye pathology code (130) with a surgery prefix (5) on their medical records to identify them as having refractive surgical procedures.

- PRK applicants are required to submit a completed "Report of Eye Evaluation" (FAA Form 8500-7) after full recovery from their refractive procedure.

- PRK applicants must meet the visual standards for the class of airman medical certificate applied for as stated in Federal Aviation Regulations Part 67.

There are over 1,200 laser systems installed worldwide, and more than 900,000 PRK/LASIK procedures have been performed (318). About 500,000 laser procedures are performed annually outside the United States. PRK has overtaken RK as the preferred refractive surgical procedure (319). It is estimated that 200,000 laser refractive procedures will be performed in the United States by the end of 1997 (320).

Projected total airmen who may opt for PRK was calculated using a mathematical model (see Figure 8) similar to that used for total PRK predictions by laser manufacturers. Our calculations project a conservative estimate that 75 airmen opted to have PRK by the end of 1996. Five years later, more than 1,200 civil airmen may elect to have PRK.

The promotional campaign for PRK has been far greater than anything associated with RK. The high-tech glitz of the "L-A-S-E-R" has enticed many individuals to have PRK procedures, without their full knowledge of the apparent risks and that safer and more suitable treatment procedures are close to being developed. It is reasonable to assume that the PRK procedure currently approved by the FDA will be replaced by more sophisticated technology and procedural applications already in development. The long-term detrimental effects and reduced vision performance resulting from PRK may adversely affect aviation safety and be an unacceptable risk for pilots, particularly air transport pilots.

PRK has been used in foreign countries for years. However, its popularity has waned as it has largely been replaced by the LASIK procedure as the refractive surgery modality of choice. Civil airmen should be advised that the FDA-approved PRK is being replaced by newer procedures and techniques that may be less detrimental to their vision and ability to obtain an FAA airman medical certificate. FDA approval for active marketing of LASIK is expected shortly.

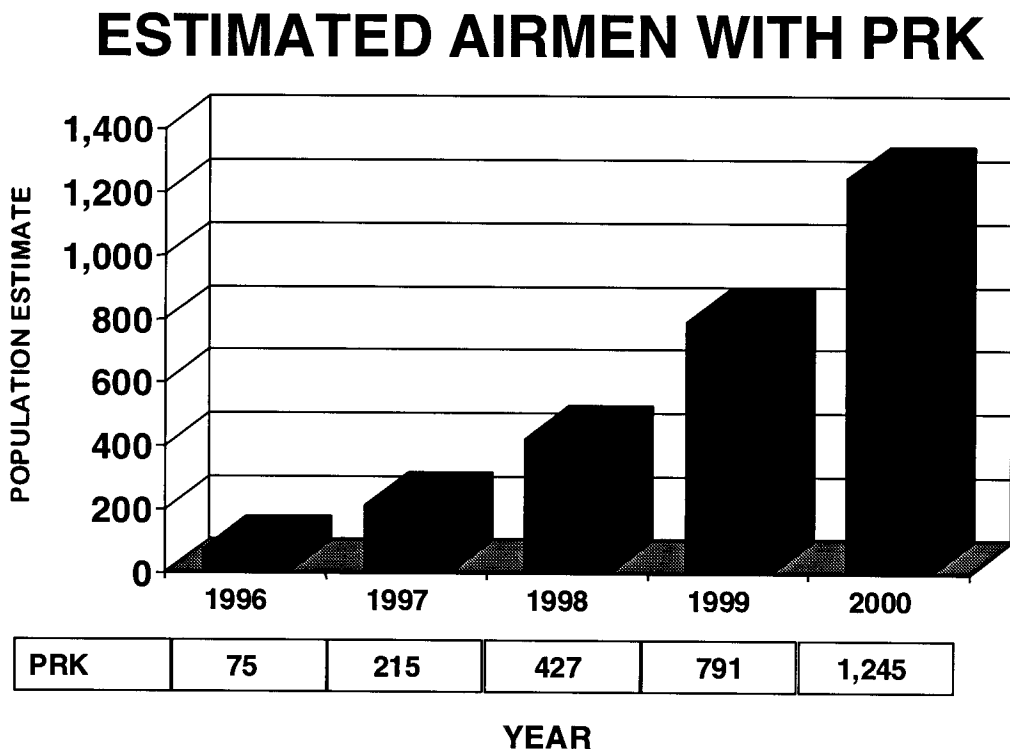


FIGURE 8

B. FACTORS FAVORING PRK IN CIVIL AIRMEN

- **Age:** PRK candidates should be between 18 to 60 years of age, and civil airmen are preponderantly in this age group category. (Note: Older patients tend to have better PRK results than younger patients (196).)

- **Refractive error:** Corrections between -1.00 to -6.00 D are most predictable. About 17% of the U.S. population are within this group (≤ -6.00 D myopia) (8); while only 3.2% have myopia of > -6.00 D. A large number of civil airmen have received flight training through the military, effectively prescreening them to this lower to mid myopic range.

- **Economic considerations:** Aviation is an expensive avocation and lucrative occupation, so civil airmen have the economic means to afford this procedure.

- **Gender Preference:** Studies suggest that males express greater interest in PRK than females (321). Civil airmen are preponderantly male (16 males to 1 female).

- **Historical interest in refractive surgery:** Civil airmen have opted for RK in substantial numbers since 1983.

C. AEROMEDICAL CERTIFICATION RECOMMENDATIONS

The successful PRK procedure is dependent upon a variety of objective and subjective criteria. Surgeons often define success as a function of the final visual acuity achieved and the lack of complications. Patients, on the other hand, may define success as the ability to exist without the encumbrances of thick glasses or contact lenses. Given these alternatives, they may tolerate associated subjective problems from PRK. However, when approached from an aeromedical safety viewpoint, these perceived minor annoyances resulting from refractive surgery may be magnified and become more important in flight activities. Early research protocols excluded pilots due to their demanding occupational vision requirements and the possibility of complications (171,172,176). For that reason, post-operative signs and symptoms need to be carefully scrutinized from the perspective of their effect on aeromedical certification (152).

- Night vision problems, which include glare, halos around lights, haze, starbursts, and dim lighting difficulties, may impair the pilot during Instrument Flight Rules (IFR) conditions (103,121,141, 322,323). Gimbel et al. (141), reported that as high as 50% of bilateral PRK patients have reduced quality of vision in dim light, 38% reduced vision in artificial lighting versus daylight, and 50% reported night driving difficulties.

- Reduced contrast sensitivity may occur from both glare and corneal haze. The visual acuity standards for civil airmen are based on high-contrast Snellen targets viewed in controlled environments. In the natural environment, visual contrast sensitivity becomes critical to optimal performance where weather elements (fog, haze, and rain) reduce contrast between targets and the background environment. Although most countries have no current aviation medical standards with respect to contrast sensitivity, an individual's ability to perceive contrast has been recognized as a critical element in overall visual performance. A procedure, such as PRK, with the potential to degrade contrast sensitivity must be scientifically evaluated to determine its impact (152). Contrast sensitivity performance may improve, as corneal haze is reduced. Prematurely accepting ill-defined reduced contrast sensitivity performance in aviators, until it is fully understood, may be aeromedically risky (152).

- The structural integrity of the eye after PRK is unknown. PRK removes a portion of corneal tissue up to 10% of the total corneal depth. Although it is assumed that any structural weakening of the eye induced by PRK would be much less than in RK, one cannot predict with absolute certainty what the corneal rigidity will be after PRK (152).

- The stability of refraction may be a problem. There is a hyperopic shift (164,197) and a period of refractive instability that slows over a 3- to 6-month period, but may continue beyond 1 year. Studies have shown that refractions may continue to be unstable for up to 26 months (102,105,213, 249,309). The post-RK cornea (3 to 5 years) has been shown to be susceptible to refractive changes in altitude (309). While the surgical mechanism is different between RK and PRK, it cannot be accurately predicted what the aviation environment's impact will be on post-PRK corneas without further investigation (309).

- Reduced BCVA may affect medical certification of professional pilots who have more stringent vision standards (102,105,114,125,174,176,211, 212). FDA trial data reports 1-3% of patients undergoing PRK lost 2 or more Snellen lines of best-corrected acuity. If only 5% of the 60 million myopes in the U.S. undergo PRK, there will be 30-90,000 PRK patients with significant acuity losses (195). When these numbers are compared to use of extended wear contact lenses, the differences are significant. Studies have shown that 0.02% develop a contact lens-related infection that results in loss of BCVA. By a conservative estimate, this would mean that the risk of loss of BCVA after PRK is 5-15X greater

than the risk with extended wear contact lens use and is 25-75X greater than the risk with daily wear soft contact lenses (324).

- Epithelial/subepithelial integrity is questionable after PRK. It is known that the corneal epithelium regenerates, and that it normally reattaches to the cornea's basement membrane and Bowman's layer. PRK removes Bowman's layer and the basement membrane over the central cornea forcing the epithelium to re-epithelialize over anterior corneal stroma. The long-term effect of this alteration of the cornea is unknown. There was some original concern that such an altered cornea might result in recurrent erosions, but the short-term experience has not supported that concern (152).

- The corneal endothelial cell layer is vital to corneal clarity. There has been no conclusive evidence of substantial problems with the corneal endothelium after PRK. However, longer-term follow-up is required to determine the clinical significance, if any, of the effects of PRK on this cell layer (152).

- Uncorrected visual acuity after PRK may not be adequate for safe operation of an aircraft. In 5-15% of PRK patients, uncorrected visual acuity of 20/40 or worse has been reported. A considerable amount of residual refractive error may persist after PRK and require correction either by glasses or contact lenses. Though approximately 75% of the post-PRK patients have refractions within ± 1.00 D of emmetropia, it appears that 40% of these will still require some type of visual correction (152). The use of contact lenses by airmen with PRK poses other clinical problems. At this time, the health of the corneal epithelium and its capacity to support the use of a contact lens is unknown (152). It is possible that post-PRK eyes wearing contact lenses may be at increased risk for corneal ulceration or complications because of the alteration in the histological relationship of the cornea. Civil airmen with PRK may not be able to tolerate contact lenses as long and under the same conditions that they did prior to PRK. The aviation environment is already a hostile one to contact lens wearers with low relative humidity, hypoxia, acceleration, etc., affecting the fit and comfort of the lenses. Additional research is needed before the full benefits from contact lens use following PRK can be realized (152).

- A "double pupil effect," resulting from the edge of the ablated optical zone being overshadowed by the dilated pupil under reduced lighting conditions, can be detrimental to aviators. This phenomenon causes retinal image degradation, glare, blurred vision, and visual

confusion. This is an important issue that deserves careful consideration, especially with night and low-light flight operations.

- Induced anisometropia, a form of monovision, may be a planned procedure for early presbyopes having PRK. Monovision, normally performed using contact lenses, is contraindicated in the *Guide for Aviation Medical Examiners* (72). Monovision may affect depth perception and reduce BCVA. Aviators should be informed of these side effects, and that ophthalmic lenses to correct PRK-induced monovision may be required.

- When bilateral PRK procedures are required, the FDA recommends that PRK be performed on one eye at a time. This allows adequate vision for the patient during the extended healing process. The healing response on the operated eye may be used by the surgeon to refine the PRK procedure on the second eye. The induced anisometropia between eye surgeries may substantially affect depth perception and require the use of a contact lens. This may become a serious problem for those patients who are contact lens intolerant. Following first eye PRK with resultant anisometropia, aeromedical certification of applicants should be delayed until the procedure is completed bilaterally.

- Aviation-related environmental and flight maneuver effects on PRK need further studies. The effects of gravito-intertial, accelerative or decelerative, and vibrational factors on PRK have yet to be determined (121).

D. OPTIONS UNDER CONSIDERATION BY FAA FOR EVALUATION OF APPLICANTS WITH PRK

- As a result of possible delayed corneal healing, an application for an airman medical certificate should be initiated no earlier than 6 months after the final post-operative eye procedure. The *Guide for Aviation Medical Examiners* states that healing is usually complete within 6 to 12 weeks after refractive surgery (72). However, it takes about 1 year for the post-PRK refraction to stabilize, and this period may be longer in the correction of higher myopes. (Note: In some countries, a waiting period of 12 months after RK is required before obtaining an aeromedical certificate. In France, any person who has refractive surgery is automatically classified as unfit to fly and must request a special dispensation; only 1 of 3 applicants is successful in obtaining this dispensation (223).)

- Medical certificates should not be issued while an applicant is using corticosteroids to modulate the corneal healing process. The use of such drugs suggests

incomplete healing, and corticosteroids often have serious side effects. One of the most serious is induced ocular hypertension (105,139, 186,252), suggesting that intraocular pressure tests be performed on all PRK applicants. (Note: A recent trend is the reducing of steroid use and substituting non-steroidal anti-inflammatory agents for shorter periods of time. However, steroids are more effective in minimizing post-PRK inflammation and corneal haze, and preventing post-operative refractive regression. Their clinical use seems unavoidable, as they continue to be prescribed by most refractive surgeons.)

- Since the primary surgeon may be less candid in identifying complications as a result of their PRK procedure, an evaluation using the FAA Form 8500-7 (Report of Eye Evaluation) by a neutral eye specialist is recommended.

- Due to some unique symptoms associated with PRK, an expanded case history is recommended. Questions about symptoms associated with PRK, such as fluctuating visual acuity, glare, halos, dry eyes, etc., should be included.

- FAA Form 8500-7 may be inadequate for monitoring PRK. Specific clinical tests for PRK may include: retinoscopy to evaluate corneal integrity and pupillary dilation impinging on the ablation border; keratometry to evaluate induced microscopic astigmatism; biomicroscopy to evaluate corneal haze and fluorescein pooling in the central cornea; and corneal topography to evaluate long-term changes.

- The addition of more sensitive vision performance tests may be needed to supplement the current aeromedical certification examination. For example, the Danish Civil Aviation Administration uses glare and contrast sensitivity to evaluate all RK applicants for aeromedical certification (325).

- The potentially large number of civil airmen that may opt for PRK requires that aeromedical certification issues be carefully studied, and that airmen with PRK be appropriately screened and prospectively followed for any future problems associated with this ophthalmic condition in aviation activities.

- Proper educational material for airmen considering PRK should be developed and distributed. (Note: A brochure developed by the Vision Research Team at CAMI has been approved for publication.)

- There is a need to continue monitoring and providing periodic feedback to the Office of Aviation Medicine on these and other new refractive surgeries

that may impact aviation safety. The literature on PRK is difficult to analyze, because treatments and procedures are continuing to be developed and refined. Historically, it is similar to the improvements in RK since the original Prospective Evaluation of Radial Keratotomy Study (or "PERK Study") of 10 years ago. Since refinements to PRK and new procedures are being studied and used successfully in clinical settings in foreign countries, their use in the United States is inevitable.

VI. SUMMARY

Refractive errors do not indicate that eyes are unhealthy. Therefore, it is important that refractive surgery procedures be safe as they are treating healthy eyes that can obtain clear and useful vision by other corrective modalities (glasses, contact lenses). Absence of complications and long-term safety should accompany a good refractive outcome. The goal of refractive surgery is to provide the patient with a stable corneal surface and the best optical performance possible. In the reporting of PRK clinical studies, it is important that other test results (glare, CSF) be included, since visual acuity and refraction alone do not fully describe the optical performance of the eye.

RK has increased in prevalence in civil airmen each year from 1983 through 1994. This increase, even in years in which RK was not recommended by many eye care practitioners due to a multitude of post-operative symptoms being reported, suggests that airmen do not feel threatened by any loss of sensory skills often associated with RK. Based on the history of RK in the civil airman population, it is believed that pilots will opt for excimer laser PRK. It is estimated that about 75 airmen will have had PRK by the end of 1996, and over 1,200 civil airmen may choose to have PRK by the year 2000.

Due to the inherent risks of refractive surgical procedures, aeromedical certification issues concerning PRK will be carefully studied. Airmen must be appropriately screened and monitored to identify problems associated with PRK and the performance of aviation activities. Factual educational materials highlighting the advantages and disadvantages for airmen considering PRK will be provided to allow airmen to make informed choices based on how this procedure may affect their aviation activities and careers. This approach is responsive to today's patients who feel a need to be proactive in their medical diagnosis and treatment.

REFERENCES

1. Waring GO III. Evaluating new refractive procedures: Free market madness versus regulatory rigor mortis. *J Refract Surg.* Sep-Oct 1995; 11(5):335-9.
2. American Optometric Association. Caring for the eyes of America: A profile of the optometric profession. 1996 ID1/196.
3. Scerra C. Lasers and optometry: Changing old lamps for new? *Optom Econ.* Winter 1996; 6(1):10-6.
4. Stein HA, Slatt BJ, Stein RM. "Refractive errors and how to correct them." In: Stein HA, Slatt BJ, Stein RM, eds. *The Ophthalmic Assistant.* St Louis MO: The CV Mosby Company; 1988:211-35.
5. Stein HA, Cheskes A, Stein RM. "Population demographics and patient selection." In: Stein HA, Cheskes A, Stein RM, eds. *The Excimer: Fundamental and Clinical Use.* Thorofare, NJ: Slack Inc; 1995:21-3.
6. Roberts J. Refraction status and motility defects of persons 4-74 years, United States, 1971-1972. (Vital and health statistics: Series 11, Data from the National Health Survey; no 206). (DHEW Publication no. (PHS) 78-1654.)
7. Allard R. Corneal refractive surgery: Part I—past and present. *Contact Lens Spectr.* Aug 1991; 5(8):44-50.
8. Wilson DR, Keeney AH. Corrective measures for myopia. *Surv Ophthalmol.* Jan-Feb 1990; 34(4):294-304.
9. Werner DL. Refractive surgery: keratomileusis and keratophakia. *J Am Optom Assoc.* Aug 1986; 57(8):590-3.
10. Maxwell WA, Nordan LT. "Optical and wound complications of keratomileusis: Incidence and treatment." In: Cavanagh DH, ed. *The Cornea: Transactions of the World Congress on the Cornea III.* New York: Raven Press Ltd; 1988.
11. Smith JA, Price FW. ALK: High hopes for high myopes. *Rev Optom.* Oct 1994; 13(10):77-84.
12. Laroche L, et al. Non-freeze myopic keratomileusis for myopia in 158 eyes. *J Refract Corneal Surg.* Jul-Aug 1994; 10(4):400-12.
13. Sarno ME, Smith RE, Schanzlin DJ. Comparison of clinical results following radial keratotomy, extended-wear contact lenses, and myopic keratomileusis. *Int Ophthalmol Clin.* Fall 1993; 23(3):167-92.
14. Scott C. Refractive corneal surgery. *Contemp Optom.* May 1990; 9(1):24-34.
15. Burillon C, Durand L, Gourraud A. Combined epikeratoplasty and homoplastic keratophakia for correction of aphakia: double curve effect. *Refract Corneal Surg.* May-Jun 1993; 9(3):214-8.
16. Dausch D, et al. "Laser correction of hyperopia." In: Salz JJ, McDonnell PJ, McDonald MB, eds. *Corneal Laser Surgery.* St. Louis, MO: Mosby Year Book Inc; 1995:237-60.
17. Durrie DS, Schumer J, Cavanaugh TB. Holmium: YAG laser thermokeratoplasty for hyperopia. *J Refract Corneal Surg.* Mar-Apr 1994; 10(suppl):S277-80.
18. Nose W, Neves RA, Schanzlin DJ, Belfort R. Intrastromal corneal ring—one-year results of first implants in human eyes: A preliminary nonfunctional eye study. *Refract Corneal Surg.* Nov-Dec 1993; 9(6):452-8.
19. Quantock AJ, Assil KK, Schanzlin DJ. Electron microscopic evaluation of intrastromal corneal rings explanted from nonfunctional human eyes. *J Refract Corneal Surg.* Mar-Apr 1994; 10(2):142-8.
20. Minarik KR. Correcting vision after RK. *Optom Manage.* Jun 1995; 30(6):34-6.
21. Anonymous. Radial keratotomy for myopia. *Ophthalmol.* Jul 1993; 100(7):1103-15.
22. Binder PS. Radial keratotomy in the 1990s and the PERK Study. *JAMA.* Feb 23 1990; 263(8):1127. Editorial.
23. Waring GO III. "Development of refractive keratotomy in the United States, 1978-1990." In: Waring GO III ed. *Refractive Keratotomy for Myopia and Astigmatism.* St. Louis, MO: Mosby Year Book; 1992; 237-57.
24. MacRae S, Cox W, Bedrossian R, Rich LF. The treatment of persistent wound leak after radial keratotomy. *Refract Corneal Surg.* Jan-Feb 1993; 9(1):62-4.
25. Marmer RH. Radial keratotomy complications. *Ann Ophthalmol.* Nov 1987; 19(11):409-11.
26. Binder PS. Vision after RK surgery. *Rev Optom.* Oct 1987; 124(10):74-5.
27. McNeill JI. Corneal incision dehiscence during penetrating keratoplasty nine years after radial keratotomy. *J Cataract Refract Surg.* Jul 1993; 19(4):542-3.

28. McDonnell PJ, Caroline PJ, Salz JJ. Irregular astigmatism after radial and astigmatic keratotomy. *Am J Ophthalmol.* Jan 1989; 107(1):42-6.
29. Binder PS. The excimer laser and radial keratotomy: Two vastly different approaches for myopia correction. *Arch Ophthalmol.* Nov 1990; 108(11):1541-2.
30. Bryant MR, Szerenyi K, Schmotzer H, McDonnell PJ. Corneal tensile strength in fully healed radial keratotomy wounds. *Invest Ophthalmol Vis Sci.* Jun 1994; 35(7):3022-31.
31. Campos M, Lee M, McDonnell PJ. Ocular integrity after refractive surgery: effects of photorefractive keratectomy, phototherapeutic keratectomy, and radial keratotomy. *Ophthalmic Surg.* Sep 1992; 23(9):598-602.
32. Lee BL, Manchee EE, Glasgow BJ. Rupture of radial and arcuate keratotomy scars by blunt trauma 91 months after incisional keratotomy. *Am J Ophthalmol.* Jul 1995; 121(1):108-10.
33. McDermott ML, Wilkinson WS, Tukel DB, Madion MP, Cowden JW, Puklin JE. Corneoscleral rupture ten years after radial keratotomy. *Am J Ophthalmol.* Nov 1990; 110(5):575-7.
34. Vinger PF, Mieler WF, Oestreicher JH, Easterbrook M. Ruptured globes following radial and hexagonal keratotomy surgery. *Arch Ophthalmol.* Feb 1996 114(2):129-34.
35. Zamora RL, Goldberg MA, Pepose JS. Presumed epithelial cyst in the anterior chamber following refractive keratotomy. *J Refract Corneal Surg.* Nov-Dec 1994; 10(6):652-5.
36. Lavenburg DJ. The state of the art radial keratotomy. *Rev Optom.* Mar 1994; 131(3):45-51.
37. Beldavs RA, Al-Ghamdi S, Wilson LA, Waring GO III. Bilateral microbial keratitis after radial keratotomy. *Arch Ophthalmol.* Apr 1993; 111(4):440.
38. Duffey RJ. Bilateral serratia marcescens keratitis after simultaneous bilateral radial keratotomy. *Am J Ophthalmol.* Feb 1995; 119(2):233-6. Letter.
39. Klinger CH, Maloney RK. Keratitis as a complication of bilateral simultaneous radial keratotomy. *Am J Ophthalmol.* Nov 1994; 118(5):680-1.
40. Leidenix MJ, Lundergan MK, Pfister D, Kastl PR, Smith RE, Mamalis N. Perforated bacterial corneal ulcer in a radial keratotomy incision secondary to minor trauma. *Arch Ophthalmol.* Dec 1994; 112(12):1513-4.
41. Leahey AB, Burkholder TO. Infectious keratitis 1 day after radial keratotomy. *Arch Ophthalmol.* Dec 1994; 112(12):1521-3.
42. Szerenyi K, McDonnell JM, Smith RE, Irvine JA, McDonnell PJ. Keratitis as a complication of bilateral simultaneous radial keratotomy. *Am J Ophthalmol.* Apr 1994; 117(4):462-7.
43. Maskin SL, Alfonso EC. Fungal keratitis after radial keratotomy. *Am J Ophthalmol.* Sep 1992; 114(3):369-70. Letter.
44. Spadea L, Dragani T, Blasi MA, Mastrofini MC, Balestrazzi E. Specular microscopy of the corneal endothelium after excimer laser photorefractive keratectomy. *J Cataract Refract Surg.* Mar 1996; 22(2):188-93.
45. Binder PS, Nayak SK, Deg JK, Zavala EY, Sugar J. An ultrastructural and histochemical study of long-term wound healing after radial keratotomy. *Am J Ophthalmol.* Mar 1987; 103(3):432-40.
46. Durand L, Monnot JP, Burillon C, Assi A. Complications of radial keratotomy: eyes with keratoconus and late wound dehiscence. *Refract Corneal Surg.* Jul-Aug 1992; 8(4):311-4.
47. Gussler JR, Miller D, Jaffe M, Alfonso EC. Infection after radial keratotomy. *Am J Ophthalmol.* Jun 1995; 119(6):798-9.
48. Geiser J, Sugar A. Radial keratotomy and corneal scarring. *Arch Ophthalmol.* Nov 1992; 110(11):1527-8.
49. Wharton KR. Corneal stellate iron lines following radial keratotomy. *J Am Optom Assoc.* May 1989; 60(5): 362-4.
50. Binder PS. Radial keratotomy and excimer laser photorefractive keratectomy for the correction of myopia. *J Refract Corneal Surg.* Jul-Aug 1994; 10(4):442-64.
51. Deitz MR, Sanders DR, Raanan MG. Progressive hyperopia in radial keratotomy. *Ophthalmol.* Oct 1986; 93(10):1284-98.
52. Deitz MR, Sanders DR, Raanan MG, DeLuca M. Long-term (5- to 12-year) follow-up of metal-blade radial keratotomy procedures. *Arch Ophthalmol.* May 1994; 112(5):614-20.

53. Waring GO III, Lynn MJ, McDonnell PJ, PERK Study Group. Results of the prospective evaluation of radial keratotomy (PERK) study 10 years after surgery. *Arch Ophthalmol*. Oct 1994; 112(10):1298-1308.
54. Duling K, Wick B. Binocular vision complication after radial keratotomy. *Am J Optom Physiol Opt*. Mar 1988; 65(3):215-23.
55. Applegate RA. Acuities through annular and central pupils after radial keratotomy. *Optom Vis Sci*. Aug 1991; 68(8):584-90.
56. Enzenauer RW, Wolter A, Cornell FM, Tucker S. Radial keratotomy in the soldier-aviator. *Mil Med*. Aug 1993; 158(8):521-8.
57. Veraart HG, van den Berg TJ, IJspeert JK, Cardozon OL. Stray light in radial keratotomy and the influence of pupil size and stray light angle. *Am J Ophthalmol*. Oct 1992; 114(4):424-8.
58. Werblin TP, Stafford GM. The Casebeer system for predictable keratorefractive surgery: One-year evaluation of 205 consecutive eyes. *Ophthalmol*. Jul 1993; 100(7):1095-102.
59. Bullimore MA, Sheedy JE, Owen D, Refractive Surgery Study Group. Diurnal visual changes in radial keratotomy: implications for visual standards. *Optom Vis Sci*. Aug 1994; 71(8):516-21.
60. Shivitz IA, Arrowsmith PN. Corneal sensitivity after radial keratotomy. *Ophthalmol*. Jun 1988; 95(6):827-32.
61. Damiano RE, Forstot SL. Extreme corneal flattening after radial keratotomy. *Am J Ophthalmol*. Dec 1991; 112(6):738. Letter.
62. MacRae S, Rich LF, Phillips D, Bedrossian R. Diurnal variation in vision after radial keratotomy. *Am J Ophthalmol*. Mar 1989; 107(3):262-7.
63. Wyzinski P. Daily refractive changes persisting after radial keratotomy. *Am J Ophthalmol*. Aug 1989; 108(2):205-6.
64. McDonnell PJ, Nizam A, Lynn MJ, Waring GO III, PERK Study Group. Morning-to-evening change in refraction, corneal curvature, and visual acuity 11 years after radial keratotomy in the prospective evaluation of radial keratotomy study. *Ophthalmol*. Feb 1996; 103(2):233-9.
65. Healy B. From the National Institutes of Health. *JAMA*. Nov 6, 1991; 266(17):2341.
66. Arrowsmith PN, Marks RG. Visual, refractive and keratometric results of radial keratotomy: Five-year follow-up. *Arch Ophthalmol*. Apr 1989; 107(4):506-11.
67. Kraff MC, Sanders DR, Karcher D, Ragnan M, DeLuca M, Neumann G. Changing practice patterns in refractive surgery: Results of a survey of the American Society of Cataract and Refractive Surgery. *J Cataract Refract Surg*. Mar 1994; 20(2):172-8.
68. Editor. Radial keratotomy for simple myopia. *JAMA*. Jul 8, 1988; 260(2):264-7.
69. Editor. Can surgery free you from glasses? *Consum Rep*. Feb 1994; 59(2):87-90.
70. Parmley V, Ng J, Gee B, Rotkis W, Mader T. Penetrating keratoplasty after radial keratotomy: A report of six patients. *Ophthalmol*. Jun 1995; 102(6):947-50.
71. Lynn MJ, Waring GO III, Kutner MH. "Predictability of refractive keratotomy." In: Waring GO III, ed. *Refractive Keratotomy for Myopia and Astigmatism*. St Louis: Mosby Year Book; 1992:341-80.
72. Department of Transportation/Federal Aviation Administration. Guide for aviation medical examiners. Washington, DC:1996; FAA Office of Aviation Medicine.
73. Aron-Rosa D, et al. Excimer laser surgery of the cornea: Qualitative and quantitative aspects of photoablation according to energy density. *J Cataract Refract Surg*. Jan 1985; 12(1):27-3.
74. Trokel SL. Evolution of excimer laser corneal surgery. *J Cataract Refract Surg*. Jul 1989; 15(4):373-83.
75. Aron-Rosa D. Worldwide update on the excimer laser. *Eyecare Technol*. May-Jun 1994; 4(3):52-7.
76. Editor. VISX submits 2-year excimer clinical data and updates FDA filing status. *AOA News*. Aug 1, 1994; 33(3):8.
77. Hahn TW, Sah WJ, Kim JH. Phototherapeutic keratectomy in nine eyes with superficial corneal diseases. *Refract Corneal Surg*. Mar-Apr 1993; 9(suppl):S115-8.
78. Hersh PS, Spinak A, Garrana R, Mayers M. Phototherapeutic keratectomy: Strategies and results in 12 eyes. *Refract Corneal Surg*. Mar-Apr 1993; 9(suppl):S90-5.

79. Goldstein M, Lowenstein A, Rosner M, Lipshitz I, Lazar M. Phototherapeutic keratectomy in the treatment of corneal scarring from trachoma. *J Refract Corneal Surg.* Mar-Apr 1994; 10 (suppl):S290-2.
80. Cotliar AM, Schubert HD, Mandel ER, Trokel SL. Excimer laser radial keratotomy. *Ophthalmol.* Feb 1985; 92(2):206-8.
81. Kerr-Muir MG, Trokel SL, Marshall J, Rothery S. Ultrastructural comparison of conventional surgical and argon fluoride excimer laser keratectomy. *Am J Ophthalmol.* Mar 1987; 103(3):448-53.
82. Schroder E. Technical concepts of an excimer laser for corneal surgery. *Dev Ophthalmol.* 1989; 18:146-53.
83. Aron-Rosa D, et al. Corneal wound healing after excimer laser keratotomy in human eye. *Am J Ophthalmol.* Mar 1987; 103(3):454-64.
84. Berns MW, Liaw LH, Oliva A, Andrews JJ, Rasmussen RE, Kimel S. An acute light and electron microscopic study of ultraviolet 193-nm excimer laser corneal incisions. *Ophthalmol.* Oct 1988; 95(10):1422-33.
85. Krueger RR. Excimer laser: a step-up in complexity and responsibility for the ophthalmic laser surgeon? *J Refract Corneal Surg.* Mar-Apr 1994; 10(2):83-6. Editorial.
86. Marshall J, Trokel SL, Rothery S, Krueger RR. Long-term healing of the central cornea after photorefractive keratectomy using an excimer laser. *Ophthalmol.* Oct 1988; 95(10):1411-21.
87. Taylor DM, et al. Human excimer laser lamellar keratectomy: A clinical study. *Ophthalmol.* May 1989; 96(5): 654-64.
88. Leroux les Jardins S, Auclin F, Roman S, Burtshy B, Leroux les Jardins J. Results of photorefractive keratectomy on 63 myopic eyes with six months minimum follow-up. *J Cataract Refract Surg.* Apr 1994; 20(suppl):S223-8.
89. Waring GO III. Development of a system for excimer laser corneal surgery. *Trans Am Ophthalmol Soc.* 1989; LXXXVII:854-893.
90. Fantes FE, Waring GO III. Effect of excimer laser radiant exposure on uniformity of ablated corneal surface. *Lasers Surg Med.* Jun 1989; 9(6):533-42.
91. Editor. Summit PRK laser conditionally okayed by FDA panel. *AOA News.* Nov 1, 1994; 33(9):1,12-13.
92. Editor. Royalties to hike procedure costs. *AOA News.* Oct 15, 1995; 34(8):10.
93. Editor. Lucky or unlucky sign? Summit: U.S. PRKs total 13,000 in first 6 months. *AOA News.* Apr 8, 1996; 34(19):1,4,8.
94. Demers P, Thompson P, Bernier RG, J Lemire J, Laflamme P. Effect of occlusive pressure patching on the rate of epithelial wound healing after photorefractive keratectomy. *J Cataract Refract Surg.* Jan-Feb 1996; 22(1):59-62.
95. Gartry DS. Treating myopia with the excimer laser: the present position. *BMJ.* Apr 15, 1995; 310(6985):979-85.
96. Sher NA, et al. 193-nm excimer photorefractive keratectomy in high myopia. *Ophthalmol.* Sep 1994; 101(9): 1575-82.
97. Epstein D, Faterholm P, Hamberg-Nyström H, Tengroth B. Twenty-four-month follow-up of excimer laser photorefractive keratectomy for myopia, refractive and visual acuity results. *Ophthalmol.* Sep 1994; 101(9): 1558-64.
98. Campos M, Hertzog L, Wang XW, Fasano AP, McDonnell PJ. Corneal surface after de-epithelization using a sharp and a dull instrument. *Ophthalmic Surg.* Sep 1992; 23(9):618-21.
99. Campos M, Raman S, Lee M, McDonnell PJ. Keratocyte loss after different methods of de-epithelization. *Ophthalmol.* May 1994; 101(5): 890-4.
100. Seiler T, McDonnell PJ. Excimer laser photorefractive keratectomy. *Surv Ophthalmol.* Sep-Oct 1995; 40(2): 89-118.
101. Seiler T, Kahle G, Kriegerowski M. Excimer laser (193-nm) myopic keratomileusis in sighted and blind human eyes. *Refract Corneal Surg.* Sep-Oct 1990; 6(5):165-73.
102. Seiler T, Wollensak J. Results of prospective evaluation of photorefractive keratectomy at 1 year after surgery. *Ger J Ophthalmol.* May 1993; 2(3):135-42.
103. Machat JJ, Tayfour F. Photorefractive keratectomy for myopia: preliminary results in 147 eyes. *Refract Corneal Surg.* Mar-Apr 1993; 9 (suppl):S16-9.
104. Fichte CM, Bell AM. Ongoing results of excimer laser photorefractive keratectomy for myopia: subjective patient impressions. *J Cataract Refract Surg.* Mar 1994; 20(2):268-70.

105. Pallikaris IG, Lambropoulos IE, Kolydas PK, Nicolopoulos NS, Kotsiras IE. Excimer laser photorefractive keratectomy for myopia: Clinical results in 96 eyes. *Refract Corneal Surg.* Mar-Apr 1993; 9(suppl):S101-02.
106. Waring GO III, Hanna KD, Fantes FE, Thompson K, Raj NS. Wound healing after excimer laser photorefractive keratectomy. *Dev Ophthalmol.* 1991; 22:150-3.
107. Shah SI, Hersh PS. Photorefractive keratectomy for myopia with a 6-mm beam diameter. *J Refract Surg.* Mar-Apr 1996; 12(2):341-6.
108. Hersh PS, Shah SI, Geiger D, Holladay JT. Corneal optical irregularity after excimer laser photorefractive keratectomy. *J Cataract Refract Surg.* Mar 1996; 22(2):197-204.
109. Litwin KL, Moreira H, Ohadi C, McDonnell PJ. Changes in corneal curvature at different laser ablative depths. *Am J Ophthalmol.* Mar 1991; 111(3):382-4. Letter.
110. Kalski RS, Sutton G, Bin Y, Lawless MA, Rogers C. Comparison of 5-mm and 6-mm ablation zones in photorefractive keratectomy for myopia. *J Refract Surg.* Jan-Feb 1996; 12(1):61-7.
111. Kaufala CJ, Lambropoulos JE, Kotsiras JE, Orfanides TE, Pallikaris JG. Stability and complications of photorefractive keratectomy over 2.5 years. *J Refract Surg.* Jan-Feb 1996; 12(1):S264-5.
112. Morris AT, Ring P, Hadden OB. Comparison of photorefractive keratectomy for myopia using 5-mm and 6-mm diameter ablation zones. *J Refract Surg.* Jan-Feb 1996; 12(suppl):S275-7.
113. Spadea L, Sabetti L, Balestrazzi E. Effect of centering excimer laser PRK on refractive results: A corneal topography study. *Refract Corneal Surg.* Mar-Apr 1993; 9(suppl):S22-5.
114. Lindstrom RL, et al. Use of the 193-nm excimer laser for myopic photorefractive keratectomy in sighted eyes: A multicenter study. *Trans Am Ophthalmol Soc.* 1991; LXXXIX:155-82.
115. Moretti M. Radial keratotomy and photorefractive keratectomy develop synergistic relationship. *Refract Corneal Surg.* Nov-Dec 1993; 9(6):409-11.
116. McDonald MB, et al. Central photorefractive keratectomy for myopia: partially sighted and normal sighted eye. *Ophthalmol.* Sep 1991; 98(9):1327-37.
117. Talley AR, et al. Results one year after using the 193-nm excimer laser for photorefractive keratectomy in mild to moderate myopia. *Am J Ophthalmol.* Sep 1994; 118(3):304-11.
118. Yavitz E. RK vs. PRK: Efficacy and outcome. *Optom Manage.* Dec 1994; 29(12):13.
119. Maguen E, Machat JJ. "Complications of photorefractive keratectomy, primarily with the VISX excimer laser." In: Salz JJ, McDonnell PJ, McDonald MB, eds. *Corneal Laser Surgery.* St. Louis MO: Mosby Year Book Inc; 1995:143-58.
120. Sher NA, et al. Excimer laser photorefractive keratectomy in high myopia: A multicenter study. *Arch Ophthalmol.* Jul 1992; 110(7):935-43.
121. Diamond S. Excimer laser photorefractive keratectomy (PRK) for myopia-present status: Aero-medical considerations. *Aviat Space Environ Med.* Jul 1995; 66(7):690-3.
122. Warnock S. Education key to patient and OD in handling PRK complications. *Prim Care Optom News.* Feb 1996; 1(1):8.
123. Cavanaugh TB, Durrie DS, Riedel SM, Hunkeler JD, Leshner MP. Topographical analysis of the centration of excimer laser photorefractive keratectomy. *J Cataract Refract Surg.* Feb 1993; 19(suppl):S136-43.
124. Seiler T, Reckmann W, Maloney RK. Effective spherical aberration of the cornea as a quantitative descriptor in corneal topography. *J Cataract Refract Surg.* Feb 1993; 19(suppl):S155-65.
125. Tuft SJ, Gartry DS, Rawe IM, Meek KM. Photorefractive keratectomy: Implications of corneal wound healing. *Br J Ophthalmol.* Apr 1993; 77(4):243-7.
126. Pender PM. Photorefractive keratectomy for myopic astigmatism: Phase IIA of the Federal Drug Administration study (12 to 18 months follow-up). *J Cataract Refract Surg.* Apr 1994; 20(suppl):S262-4.
127. Amano S, Tanaka S, Shimizu K. Topographical evaluation of centration of excimer laser myopic photorefractive keratectomy. *J Cataract Refract Surg.* Nov 1994; 20(6):616-9.
128. Tengroth B, Epstein D, Fagerholm P, Hamberg-Nyström H, Fitzsimmons TD. Excimer laser photorefractive keratectomy for myopia: Clinical results in sighted eyes. *Ophthalmol.* May 1993; 100(5):739-45.

129. Klyce SD, Smolek MK. Corneal topography of excimer laser photorefractive keratectomy. *J Cataract Refract Surg.* Feb 1993; 19(suppl):S122-30.
130. Krueger RR, Binder PS, McDonnell PJ. "The effects of excimer laser photoablation on the cornea." In: Salz JJ, McDonnell PJ, McDonald MB, eds. *Corneal Laser Surgery.* St. Louis MO: Mosby Year Book Inc; 1995:11-44.
131. Maguire LJ, Bechara S. Epithelial distortions at the ablation zone margin after excimer laser photorefractive keratectomy for myopia. *Am J Ophthalmol.* Jun 1994; 117(6):809-10.
132. Dello Russo J. Night glare and excimer laser ablation diameter. *J Cataract Refract Surg.* Jul 1993; 19(4):575.
133. Aktunç R, Aktunç T. Centration of excimer laser photorefractive keratectomy and changes in astigmatism. *J Refract Surg.* Jan-Feb 1996; 12(suppl):S268-71.
134. Dausch D, Klein R, Schroder E. Excimer laser photorefractive keratectomy for hyperopia. *Refract Corneal Surg.* Jan-Feb-1993; 9(1):20-8.
135. Caubet E. Cause of subepithelial corneal haze over 18 months after photorefractive keratectomy for myopia. *Refract Corneal Surg.* Mar-Apr 1993; 9(suppl):S65-70.
136. Kim K-S, Lee J-H, Edelhauser HF. Corneal epithelial permeability after excimer laser photorefractive keratectomy. *J Cataract Refract Surg.* Jan-Feb 1996; 11(1):44-50.
137. Shieh E, Moreira H, D'Arcy J, Clapham TN, McDonnell PJ. Quantitative analysis of wound healing after cylindrical and spherical excimer laser ablations. *Ophthalmol.* Jul 1992; 99(7):1050-5.
138. Fantes FE, Hanna KD, Waring GO III, Pouliquen Y, Thompson KP, Savoldelli M. Wound healing after excimer laser keratomileusis (photorefractive keratectomy) in monkeys. *Arch Ophthalmol.* May 1990; 108(5):665-75.
139. Seiler T, Derse M, Pham T. Repeated excimer laser treatment after photorefractive keratectomy. *Arch Ophthalmol.* Sep 1992; 110(9):1230-3.
140. Wu WCS, Stark WJ, Green WR. Corneal wound healing after 193-nm excimer laser keratectomy. *Arch Ophthalmol.* Oct 1991; 109(10):1426-32.
141. Gimbel HV, Van Westenbrugge JA, Johnson WH, Willerscheidt AB, Sun R, Ferenowicz M. Visual, refractive, and patient satisfaction results following bilateral photorefractive keratectomy for myopia. *Refract Corneal Surg.* Mar-Apr 1993; 9(suppl):S5-10.
142. Seiler T, Hubscher HJ, Genth U. Corneal curvature change immediately after PRK as detected by Scheimpflug photography. *Invest Ophthalmol Vis Sci.* Mar 1993; 34(suppl):S703. Abstract.
143. Goodman GL, Trokel SL, Stark WJ, Munneralyn CR, Greene R. Corneal healing following laser refractive keratectomy. *Arch Ophthalmol.* Dec 1989; 107(12):1799-1803.
144. Sher NA, et al. The use of the 193-nm excimer laser for myopic photorefractive keratectomy in sighted eyes: A multicenter study. *Arch Ophthalmol.* Nov 1991; 109(11):1525-30.
145. Salz JJ, Maguen E, Macy JJ, Papaioannou T, Hofbauer J, Nesburn AB. One-year results of excimer laser photorefractive keratectomy for myopia. *Refract Corneal Surg.* Jul-Aug 1992; 8(4):269-73.
146. Thompson KP. "Photorefractive keratectomy." In: Stamper RL, Thompson KP, Waring GO III, eds. *Contemporary Refractive Surgery: Ophthalmology Clinics of North America.* Philadelphia, PA: W B Saunders Company; Dec 1992; 5(4):745-51.
147. Vrabec MP, McDonald MB, Chase DS, Aitken PA, Varnell RJ. Traumatic corneal abrasions after excimer laser keratectomy. *Am J Ophthalmol.* Jul 1993; 116(1):101-2.
148. Ditzel K, Anschutz T, Schroder E. Photorefractive keratectomy to treat low, medium, and high myopia: A multicenter study. *J Cataract Refract Surg.* Mar 1994; 20(2):234-8.
149. Citron C. Unpredictable corneal cicatrization. *Arch Ophthalmol.* Nov 1990; 108(11):1540-1.
150. Dausch D, Landes M, Klein R, Schroder E. Phototherapeutic keratectomy in recurrent corneal epithelial erosion. *Refract Corneal Surg.* Nov-Dec 1993; 9(6):419-24.
151. Seiler T, Matallana M, Sendler S, Bende T. Does Bowman's layer determine the biomechanical properties of the cornea? *Refract Corneal Surg.* Mar-Apr 1992; 8(2):139-42.

152. Ivan DJ. Photorefractive keratectomy (PRK) in the military aviator: an aeromedical expose. AGARD conference proceedings 553. *The Clinical Basis for Aeromedical Decision Making*. Neuilly-Sur-Seine, France: AGARD; April 1994; 30-1-30-18. AGARD publication AD A286 215.
153. McDonnell PJ. Excimer laser corneal surgery: New strategies and old enemies. *Invest Ophthalmol Vis Sci*. Jan 1995; 36(1):4-8.
154. Tuft SJ, Zabel RW, Marshall J. Corneal repair following keratectomy, a comparison between conventional surgery and laser photoablation. *Invest Ophthalmol Vis Sci*. Aug 1989; 30(8):1769-77.
155. Koch JW, Lang GK, Naumann COH. Endothelial reaction to perforating and non perforating excimer laser excisions in rabbits. *Refract Corneal Surgery*. May-Jun 1991; 7(3):214-22.
156. Marshall J, Trokel SL, Rothery S, Schubert HD. An ultrastructural study of corneal incisions induced by an excimer laser at 193-nm. *Ophthalmol*. Jun 1985; 92(6):749-58.
157. Amano S, Shimizu K. Corneal endothelial changes after excimer laser photorefractive keratectomy. *Am J Ophthalmol*. Dec 1993; 116(6):692-4.
158. Carones F, Brancato R, Venturi E, Mocico A. The corneal endothelium after myopic excimer laser photorefractive keratectomy. *Arch Ophthalmol*. Jul 1994; 112(7):920-4.
159. Del Pero RA, et al. A refractive and histopathologic study of excimer laser keratectomy in primates. *Am J Ophthalmol*. Apr 1990; 109(4):419-29.
160. Marshall J, Trokel SL, Rothery S, Krueger RR. Photoablative reprofiling of the cornea using an excimer laser: Photorefractive keratectomy. *Laser Ophthalmol*. Jan 1986; 1(1):21-48.
161. Editor. FDA details required reading for PRK candidates. *AOA News*. Apr 8, 1996; 34(19):9.
162. Seiler T, Wollensak J. Myopic photorefractive keratectomy with the excimer laser: One-year follow-up. *Ophthalmol*. Aug 1991; 98(8):1156-63.
163. Epstein AB. Test yourself on PRK. *Optom Manage*. Jan 1996; 31(1):29,32-33,36-38.
164. Dutt S, Steinert RF, Raizman MB, Puliafito CA. One-year results of excimer laser photorefractive keratectomy for low to moderate myopia. *Arch Ophthalmol*. Nov 1994; 112(11):1424-36.
165. Vajpayee RB, McCarty CA, Aldred GF, Taylor HR. Over correction after excimer laser treatment of myopia and myopic astigmatism. *Arch Ophthalmol*. Mar 1996; 114(3):252-6.
166. Talley AR, et al. Use of the 193-nm excimer laser for photorefractive keratectomy in low to moderate myopia. *J Cataract Refract Surg*. Mar 1994; 20(2):239-42.
167. Snyder R, Klein P. Laser vision correction: Part 2 (pre-treatment, treatment, & post-treatment). *Contact Lens Spectr*. Feb 1996; 11(2):30-5.
168. Lavery FL. Photorefractive keratectomy in 472 eyes. *Refract Corneal Surg*. Mar-Apr 1993; 9(suppl):S98-100.
169. Brancato R, et al. Excimer laser photorefractive keratectomy for myopia: Results 1165 eyes. *Refract Corneal Surg*. Mar-Apr 1993; 9(2):95-104.
170. Taylor HR, McCarty CA, Aldred GF. Predictability of excimer laser treatment of myopia. *Arch Ophthalmol*. Mar 1996; 114(3):248-51.
171. Gartry DS, Kerr-Muir MG, Lohmann CP, Marshall J. The effect of topical corticosteroids on refractive outcome and corneal haze after photorefractive keratectomy. *Arch Ophthalmol*. Jul 1993; 110(7):944-52.
172. Gartry DS, Kerr-Muir MG, Marshall J. Photorefractive keratectomy with an argon fluoride excimer laser: A clinical study. *Refract Corneal Surg*. Nov-Dec 1991; 7(6):420-35.
173. Salz JJ, et al. A two-year experience with excimer laser photorefractive keratectomy for myopia. *Ophthalmol*. Jun 1993; 100(6):873-82.
174. Maguen E. et al. Results of excimer laser photorefractive keratectomy for the correction of myopia. *Ophthalmol*. Sep 1994; 101(9):1548-57.
175. Ficker LA, et al. Excimer laser photorefractive keratectomy for myopia: 12 month follow-up. *Eye*. 1993; 7: 617-24.
176. Gartry DS, Kerr-Muir MG, Marshall J. Excimer laser photorefractive keratectomy: 18 month follow-up. *Arch Ophthalmol*. Aug 1992; 99(8):1209-19.
177. Mader TH, Schallhorn SC, Blanton CL. Refractive changes during prolonged exposure to altitude following refractive surgery. Ft. Belvoir, FL: U.S. Army Medical Research and Materials Command; Oct 1994; Defense Technical Information Center Publication No. 94MM4576.

178. Kim JH, Hahn TW, Lee YC, Sah WJ. Photorefractive keratectomy in 202 myopic eyes: One year results. *Refract Corneal Surg.* Mar-Apr 1993; 9(suppl):S11-6.
179. Piebenga LW, Matta CS, Deitz MR, Tauber J, Irving JW, Sabates FN. Excimer photorefractive keratectomy for myopia. *Ophthalmol.* Sep 1993; 100(9):1335-45.
180. Dausch D, Klein R, Landes M, Schroder E. Photorefractive keratectomy to correct astigmatism with myopia or hyperopia. *J Cataract Refract Surg.* Apr 1994; 20(suppl):S252-6.
181. Matta CS, Piebenga LW, Deitz MR, Tuber J. Excimer retreatment for myopic photorefractive keratectomy failures. *Ophthalmol.* Mar 1996; 103(3):444-51.
182. Snibson GR, McCarty CA, Aldred GF, Levin S, Taylor HR. Retreatment after excimer laser photorefractive keratectomy. *Am J Ophthalmol.* Mar 1996; 121(3):250-7.
183. Kelly HG. Get ready for the excimer laser. *Rev Optom.* Feb 1994; 131(2):53-8.
184. Snibson GR, Carson CA, Aldred GF, Taylor HR. One-year evaluation of excimer laser photorefractive keratectomy for myopia and myopic astigmatism. *Arch Ophthalmol.* Aug 1995; 113(8):944-1000.
185. Hersh PS, Patel R. Correction of myopia and astigmatism using an ablatable mask. *J Refract Corneal Surg.* Mar-Apr 1994; 10(suppl):S250-4.
186. Lawless MA, Roger C, Cohen P. Excimer laser photorefractive keratectomy: 12 months' follow-up. *Med J Aust.* Oct 18, 1993; 159(8):535,538.
187. Gilbert ML. Corneal topography: Refining excimer results. *Eyecare Technol.* May-Jun 1994; 4(3): 65,69,71-2.
188. Spigelman AV, et al. Treatment of myopic astigmatism with the 193-nm excimer laser utilizing aperture elements. *J Cataract Refract Surg.* Apr 1994; 20(suppl):S258-61.
189. Piebenga LW, Matta CS, Deitz MR, Tauber J. Two-zone excimer photorefractive keratectomy for moderate myopia: Six- to 18-month follow-up. *Ophthalmol.* Jul 1995; 102(7):1054-9.
190. Sealring RD. How FDA handled Summit's request. *Refract Surg Outlook.* Winter 1995; 1(1):2,4.
191. Kim JH, Hahn TW, Lee YC, Sah WJ. Excimer laser photorefractive keratectomy for myopia: Two-year follow-up. *J Cataract Refract Surg.* Mar 1994; 20(2):229-33.
192. Hong JC, Salz JJ. Retrospective comparison of photorefractive keratectomy and radial keratotomy. *J Refract Surg.* Nov-Dec 1995; 11(6):477-84.
193. Nizam A, et al. Stability of refraction and visual acuity during 5 years in eyes with simple myopia. *Refract Corneal Surg.* Nov-Dec 1992; 8(6):439-47.
194. Braunstein RE, Jain S, McCally RL, Stark WJ, Connolly PJ, Azar DT. Objective measurement of corneal light scattering after excimer laser keratectomy. *Ophthalmol.* Mar 1996; 103(3):439-43.
195. Zadnick K, Mutti DO. PRK vs. contact lenses: The risk is relative. *Contact Lens Spectr.* Jan 1996; 11(1):12.
196. Liu JC, McDonald MB, Varnell R, Andrade HA. Myopic excimer laser photorefractive keratectomy: An analysis of clinical correlations. *Refract Corneal Surg.* Sep-Oct 1990; 6(5):321-8.
197. Krueger RR, McDonnell PJ. Progressive hyperopia after excimer laser refractive keratectomy. *Am J Ophthalmol.* May 1994; 117(5):668-70.
198. Buratto L, Ferrari M. Photorefractive keratectomy for myopia from 6.00 D to 10.00 D. *Refract Corneal Surg.* Mar-Apr 1993; 9(suppl):S34-6.
199. Thompson KP, Steinert RF, Daniel J, Stulting D. "Photorefractive keratectomy with the Summit excimer laser: The phase III U.S. results." In: Salz JJ, McDonnell PJ, McDonald MB, eds. *Corneal Laser Surgery*. St. Louis MO: Mosby Year Book Inc; 1995:57-63.
200. O'Brart DPS, Corbett MC, Verma S, Kerr-Muir MG, Marshall J. Effects of ablation diameter, depth, and edge contour on the outcome of photorefractive keratectomy. *J Refract Surg.* Jan-Feb 1996; 12(1):50-60.
201. Heitzmann J, Binder PS, Kassab BS, Nordan LT. The correction of high myopia using the excimer laser. *Arch Ophthalmol.* Dec 1993; 111(12): 1627-34.
202. Ehlers N, Hjortdal JO. Excimer laser refractive keratectomy for high myopia: 6-month follow-up of patients treated bilaterally. *Acta Ophthalmol.* Oct 1992; 70(5):578-86.

203. Esente S, Passarelli N, Falco L, Passani F, Guidi D. Contrast sensitivity under photopic conditions in photorefractive keratectomy: A preliminary study. *Refract Corneal Surg.* Mar-Apr 1993; 9(suppl):S70-2.
204. Tengroth B, Fagerholm P, Söderberg P, Hamberg-Nyström H, Epstein D. Effect of corticosteroids in postoperative care following photorefractive keratectomies. *Refract Corneal Surg.* Mar-Apr 1993; 9(suppl):S61-4.
205. Weinstock SJ, Machat JJ. Excimer laser keratectomy for the correction of myopia. *CLAO J.* Apr 1993; 19(2):133-8.
206. Ramirez-Florez S, Maurice DM. Inflammatory cells, refractive regression and haze after excimer laser PRK. *J Refract Surg.* Mar-Apr 1996; 12(2):370-81.
207. Lindstrom RL, et al. Excimer laser photorefractive keratectomy in high myopia: A multicenter study. *Trans Am Ophthalmol Soc.* 1992; LXXX:277-301.
208. Lazzaro DR, Haight DH, Belmont SC, Gibratler RP, Aslanides IA, Odrigh MG. Excimer laser keratectomy for astigmatism occurring after penetrating keratoplasty. *Ophthalmol.* Mar 1996; 103(3): 458-64.
209. Timo T, Mustonen R, Tarkkanen A. Management of dry eye may reduce haze after excimer laser photorefractive keratectomy. *Refract Corneal Surg.* Jul-Aug 1993; 9(4):306.
210. McDonald MB, et al. Central photorefractive keratectomy for myopia: The blind eye study. *Arch Ophthalmol.* Jun 1990; 108(6):799-808.
211. van Saarloos PP, Constable IJ. Excimer laser keratectomy. *Aust N Z J Ophthalmol.* Aug 1992; 20(3):271-2.
212. Tutton MK, et al. Photorefractive keratectomy for myopia: 6-month results in 95 eyes. *Refract Corneal Surg.* Mar-Apr 1993; 9(suppl):S103-4.
213. Gipson IK. Corneal epithelial and stromal reactions to excimer laser photorefractive keratectomy. *Arch Ophthalmol.* Nov 1990; 108(11): 1539-40.
214. Georgaras SP, Neos G, Margetis SP, Tzenaki M. Correction of myopic anisometropia with photorefractive keratectomy in 15 eyes. *Refract Corneal Surg.* Mar-Apr 1993; 9(suppl):S29-34.
215. Tavola A, Brancato R, Galli L, Carones F, Esente S. Photorefractive keratectomy for myopia: Single vs. double-zone treatment in 166 eyes. *Refract Corneal Surg.* Mar-Apr 1993; 9(suppl):S48-52.
216. Durrie DS, Leshner MP, Cavanaugh TB. Classification of variable clinical response after photorefractive keratectomy for myopia. *J Refract Surg.* Sep-Oct 1995; 11(5):348-57.
217. Butuner Z, Elliott DB, Gimbel HV, Slimmon S. Visual function one year after excimer laser photorefractive keratectomy. *J Refract Corneal Surg.* Nov-Dec 1994; 10(6):625-30.
218. Ambrosio G, Cennamo G, DeMarco R, Lofferdo L, Rosa N, Sabastiani A. Visual function before and after photorefractive keratectomy for myopia. *J Refract Corneal Surg.* Mar-Apr 1994; 10(2):129-36.
219. Seiler T, Genth U, Holschbach A, Derse M. Aspheric photorefractive keratectomy with excimer laser. *Refract Corneal Surg.* May-Jun 1993; 9(3):166-72.
220. Pallikaris IG, et al. Tracker-assisted photorefractive keratectomy for myopia -1 to -6 diopters. *J Refract Surg.* Jan-Feb 1996; 12(1):240-7.
221. Muller-Stolzenburg NW, Muller GJ, Buchwald HJ, Schründer S. UV exposure of the lens during 193-nm excimer laser corneal surgery. *Arch Ophthalmol.* Jul 1990; 108(7):915-6.
222. Seiler T, Bende T, Winckler K, Wollensak J. Side effects in excimer corneal surgery: DNA damage as a result of 193-nm excimer laser radiation. *Graefes Arch Clin Exp Ophthalmol.* May-Jun 1988; 226(3):273-6.
223. Corbe C, Jacquelin P, Pedepat P, Pynson J, Boissin JP. Aircrew fitness decisions and advances in refractive surgery techniques. *Ger J Ophthalmol.* May 1993; 2(3):146-9.
224. Epstein RJ, Robin JB. Corneal graft rejection episode after excimer laser phototherapeutic keratectomy. *Arch Ophthalmol.* Feb 1994; 112(2):157.
225. Tsubota K, Toda I, Itoh S. Reduction of subepithelial haze after photorefractive keratectomy by cooling the cornea. *Am J Ophthalmol.* Jun 1993; 115(6):820-1.
226. Karpecki PM, Smith JM, Durrie DS. What you can do to improve PRK outcomes. *Rev Optom.* Mar 1996; 133(3):127-33.

227. Editor. Refractive surgeons debate RK, PRK, LASIK at academy meeting. *Prim Care Optom News*. Feb 1996; 1(1):9,12-3.
228. Biro S. "Vigorous healers" are best candidates for haze after PRK. *Prim Care Optom News*. Feb 1996; 1(1):18.
229. Andrade HA, McDonald MB, Lui JC, Abdelmegeed M, Varnell R, Sunderland G. Evaluation of an opacity lensometer for determining corneal clarity following excimer laser photorefractive keratectomy. *Refract Corneal Surg*. Sep-Oct 1990; 6(5):346-51.
230. Allemann N, et al. High-frequency ultrasound quantitative analyses of corneal scarring following excimer laser keratectomy. *Arch Ophthalmol*. Jul 1993; 111(7):968-73.
231. Haight DH, Auran JD, Koester CJ. In vivo confocal scanning slit microscopy of the human corneal after excimer laser photorefractive keratectomy. *Invest Ophthalmol Vis Sci*. Mar 1993; 34(suppl): S703. Abstract.
232. Henson DB. "Optical methods for measurement of ocular parameters." In: Charman WN, ed. *Visual Optics and Instrumentation*. Boca Raton, FL: CRC Press Inc; 1991:371-98.
233. Lohmann CP, Timberlake CT, Fitzke FW, Gartry DS, Kerr-Muir M, Marshall J. Corneal light scattering after excimer laser photorefractive keratectomy: The objective measurement of haze. *Refract Corneal Surg*. Mar-Apr 1992; 8(2):114-21.
234. Seiler T, Holschbach A. Central corneal iron deposit after photorefractive keratectomy. *Ger J Ophthalmol*. May 1993; 2(3):143-5.
235. Salorio DP, et al. Photorefractive keratectomy for myopia: 18-month results in 178 eyes. *Refract Corneal Surg*. Mar-Apr 1993; 9(suppl):S108-10.
236. Stein RM, Stein HA, Cheskes A, Symons S. Photorefractive keratectomy and postoperative pain. *Am J Ophthalmol*. Mar 1993; 117(3):403-5.
237. Verma S, Corbett MC, Marshall J. A prospective, randomized, double-masked trial to evaluate the role of topical anesthetics in controlling pain after photorefractive keratectomy. *Ophthalmol*. Dec 1995; 102(12):1918-24.
238. McCarty CA, Garrett SKM, Aldred GF, Taylor HR. Assessment of subjective pain following photorefractive keratectomy. *J Refract Surg*. Mar-Apr 1996; 12(2):365-9.
239. Arshinoff S, D'Addario D, Sadler C, Bilotta R, Johnson TJ. Use of topical non-steroidal anti-inflammatory drugs in excimer laser photorefractive keratectomy. *J Cataract Refract Surg*. Apr 1994; 20(suppl):S216-22.
240. Verma S, Marshall J. Control of pain after photorefractive keratectomy. *J Refract Surg*. Mar-Apr 1996; 12(2):258-64.
241. Campos M, Hertzog L, Garbus JJ, McDonnell PJ. Corneal sensitivity after photorefractive keratectomy. *Am J Ophthalmol*. Jul 1992; 114(1):51-4.
242. Tervo K, Latvala TM, Tervo TMT. Recovery of corneal innervation following photorefractive keratoablation. *Arch Ophthalmol*. Nov 1994; 112(11):1466-70.
243. Sher NA, et al. Topical diclofenac in the treatment of ocular pain after excimer photorefractive keratectomy. *Refract Corneal Surg*. Nov-Dec 1993; 9(6):425-36.
244. Epstein D, Tengroth B, Fagerholm P, Hamberg-Nyström H. Excimer retreatment of regression after photorefractive keratectomy. *Am J Ophthalmol*. Apr 1994; 117(4):456-61.
245. Komamicky GS. Case report: Tracking late-onset haze in a post-PRK patient. *Rev Optom*. Aug 1996; 133(8):86-9.
246. Scialdone A, Carones F, Bertuzzi A, Brancato R. Randomized study of single vs. double exposure in myopic PRK. *Refract Corneal Surg*. Mar-Apr 1993; 9(suppl):S41-3.
247. van Saarloos PP, Constable IJ. Improved excimer laser photorefractive keratectomy system. *Lasers Surg Med*. Feb 1993; 13(2):189-96.
248. McDonald MB, Frantz JM, Klyce SD. One-year refractive results of central photorefractive keratectomy for myopia in the non-human primate cornea. *Arch Ophthalmol*. Jan 1990; 108(1):40-7.
249. Binder PS. Excimer laser photoablation: Clinical results and treatment of complications in 1992. *Arch Ophthalmol*. Sep 1992; 110(9):1221-2.
250. Ryan R, DePaolis M. Post-operative management of the PRK patient. *Contact Lens Spectr*. Oct 1994; 9(10):57.
251. Fitzsimmons TD, Fagerholm P, Tengroth B. Steroid treatment of myopic regression: Acute refractive and topographic changes in excimer photorefractive keratectomy patients. *Cornea*. Jul 1993; 12(4):358-61.

252. O'Brart DPS, et al. The effects of topical corticosteroids and plasmin inhibitors on refractive outcome, haze, and visual performance after photorefractive keratectomy. *Ophthalmol.* Sep 1994; 101(9):1565-74.
253. McDonnell PJ, Moreira H, Clapham TN, D'Arcy J, Munnerlyn CR. Photorefractive keratectomy for astigmatism: Initial clinical results. *Arch Ophthalmol.* Oct 1991; 109(10):1370-3.
254. Meyer D, Gimbel HV, Van Westenbrugge JA. Adrenergic/anticholinergic responses after photorefractive keratectomy. *J Cataract Refract Surg.* Nov 1991; 17(6):862.
255. Lohmann CP, Gartry DS, Kerr-Muir MG, Timberlake G, Fitzke F, Marshall J. "Haze" in photorefractive keratectomy: Its origins and consequences. *Lasers and Light in Ophthalmol.* 1991; 4:15-34.
256. Talamo JH, Gollamundi S, McDonnell PJ. The influence of mitomycin C or corticosteroids on cornea wound healing after excimer laser photoablation. *Invest Ophthalmol Vis Sci.* 1990; 33(suppl): S144.
257. Lin DTC, Sutton HF, Berman M. Corneal topography following excimer photorefractive keratectomy for myopia. *J Cataract Refract Surg.* Feb 1993; 19(suppl):S149-54.
258. Krueger RR, Saedy NF, McDonnell PJ. Clinical analysis of steep central islands after excimer laser photorefractive keratectomy. *Arch Ophthalmol.* Apr 1996; 114(4):377-81.
259. Gilbert ML. Corneal topography: In search of the excimer islands. *Eyecare Technol.* Fall 1993; 3(3):23,24, 26,28.
260. Lin DTC. Corneal topographic analysis after excimer photorefractive keratectomy. *Ophthalmol.* Aug 1994; 101(8):1432-9.
261. Parker PJ, Klyce SD, Rayan BL. Central topographic islands following photorefractive keratectomy. *Invest Ophthalmol Vis Sci.* Mar-Apr 1993; 34(suppl):S803. Abstract.
262. Bor Z, et al. Plume emission, shock wave and surface wave formation during excimer laser ablation of the cornea. *Refract Corneal Surg.* Mar-Apr 1993; 9(suppl):S111-5.
263. Krueger RR, Krasinski JS, Radzewicz C, Stonecipher KG, Rowsey JJ. Photography of shock waves during excimer laser ablation of the cornea: Effect of helium gas on propagation velocity. *Cornea.* Jul 1993; 12(4):330-4.
264. Puliafito CA, Stern D, Krueger RR, Mandel ER. High-speed photography of excimer laser ablation of the cornea. *Arch Ophthalmol.* Sep 1987; 105(9):1255-69.
265. Campos M, et al. Ablation rates and surface ultrastructure of 193-nm excimer laser keratectomies. *Invest Ophthalmol Vis Sci.* Jul 1993; 34(8):2493-500.
266. Hanna KD, Pouliquen YM, Waring GO III, Savoldelli M, Fantes F, Thompson KP. Corneal wound healing in monkeys after repeated excimer laser photorefractive keratectomy. *Arch Ophthalmol.* Sep 1992; 110(9): 1286-91.
267. Campos M, Cuevas K, Shieh E, Garbus JJ, McDonnell PJ. Corneal wound healing after excimer laser ablation in rabbits: Expanding versus contracting apertures. *Refract Corneal Surg.* Sep-Oct 1992; 8(5):378-81.
268. Krueger RR, Talamo JH, McDonald MB, Varnell RJ, Wagoner MD, McDonnell PJ. Clinical analysis of excimer laser photorefractive keratectomy using a multiple zone technique for severe myopia. *Am J Ophthalmol.* Mar 1995; 119(3):263-74.
269. Sinbawy A, McDonnell PJ, Moreira H. Surface ultrastructure after excimer laser ablation: Expanding vs. contracting apertures. *Arch Ophthalmol.* Nov 1991; 109(11):1531-3.
270. Siganos DS, Pallikaris IG, Lambropoulos JE, Koufala CJ. Keratometric readings after photorefractive keratectomy are unreliable for calculating IOL power. *J Refract Surg.* Jan-Feb 1996; 12(suppl):S278-9.
271. Fyodorov SN, et al. PRK using an absorbing cell delivery system for correction of myopia from 4 to 26 D in 3251 eyes. *Refract Corneal Surg.* Mar-Apr 1993; 9(suppl):S123-4.
272. Lindstrom RL, Zabel RW. Myopic excimer laser keratectomy: A preliminary report. *Dev Ophthalmol.* 1991; 22:1-10.
273. Cho YS, Kim CG, Kim WB, Kim CW. Multi-step photorefractive keratectomy for high myopia. *Refract Corneal Surg.* Mar-Apr 1993; 9(suppl):S37-41.

274. Dausch D, Klein R, Schroder E, Dausch B. Excimer laser photorefractive keratectomy with tapered transition zone for high myopia: A preliminary report of six cases. *J Cataract Refract Surg.* Sep 1993; 19(5):590-4.
275. Kim JH, Hahn TW, Lee YC, Sah WJ. Clinical experience of two-step photorefractive keratectomy in 19 eyes with high myopia. *Refract Corneal Surg.* Mar-Apr 1993; 9(suppl):S44-7.
276. Pop M, Aras M. Multi-zone/multi-pass photorefractive keratectomy: Six month results. *J Cataract Refract Surg.* Nov 1995; 21(6):633-43.
277. Brancato R, Carones F, Trabucchi G, Scialdone A, Tavola A. The erodible mask in photorefractive keratectomy for myopia and astigmatism. *Refract Corneal Surg.* Mar-Apr 1993; 9(suppl):S125-30.
278. Cherry PM, Tutton MK, Bell AM, Neave C, Fichte C. Treatment of myopia stigmatism with photorefractive keratectomy using an erodible mask. *J Refract Corneal Surg.* Mar-Apr 1994; 10(suppl):S239-45.
279. Friedman MD, et al. OmniMed II: A new system for use with the emphasis erodible mask. *J Refract Corneal Surg.* Mar-Apr 1994; 10(suppl):S267-73.
280. Gobbi PG, Carones F, Scagliotti F, Venturi E, Brancato R. A simplified method to perform photorefractive keratectomy using an erodible mask. *J Refract Corneal Surg.* Mar-Apr 1994; 10(suppl):S246-9.
281. Seiler T, Bende T, Wollensak J, Trokel SL. Excimer laser keratectomy for correction of astigmatism. *Am J Ophthalmol.* Feb 1988; 105(2):117-24.
282. Editor. Lasers proving useful in treating astigmatism. *AOA News.* Jun 1, 1992; 30(23):5,8.
283. Taylor HR, Guest GS, Kelly P, Alpina NA. Comparison of excimer laser treatment of astigmatism and myopia. *Arch Ophthalmol.* Dec 1993; 111(12):1621-6.
284. Lipshitz I, Lowenstein A, Lazar M. Comparison of excimer laser treatment of astigmatism and myopia. *Arch Ophthalmol.* Dec 1994; 112(12):1509-10.
285. Colliac JP, Shamas HJ, Bart DJ. Photorefractive keratectomy for the correction of myopia and astigmatism. *Am J Ophthalmol.* Mar 1994; 117(3):369-80.
286. Ludwig K, Schaffer P, Gross H, Lasser T, Kampik A. Mathematical simulation of retinal image contrast after photorefractive keratectomy with a diaphragm mask. *J Refract Surg.* Jan-Feb 1996; 12(1):248-53.
287. Krueger RR, Wang XW, Rudisill M, Trokel SL, McDonnell PJ. Diffractive smoothing of excimer laser ablation using a defocused beam. *J Refract Corneal Surg.* Jan-Feb 1994; 10(1):2-6.
288. Hanna KD, Chastang JC, Pouliquen YM, Renard G, Asfar L, Waring GO III. A rotary slit delivery system for excimer laser refractive keratoplasty. *Am J Ophthalmol.* Mar 1987; 103(3):474.
289. Hanna KD, Chastang JC, Asfar L, Sampson J, Pouliquen Y, Waring GO III. Scanning slit delivery system. *J Cataract Refract Surg.* Jul 1989; 15(4):390-6.
290. Durrie DS, Schumer J, Cavanaugh TB. Photorefractive keratectomy for residual myopia after previous refractive keratotomy. *J Refract Corneal Surg.* Mar-Apr 1994; 10(suppl):S235-8.
291. Lipshitz I, Lowenstein A, Lazar M. Astigmatic keratotomy followed up photorefractive keratectomy in the treatment of compound myopic astigmatism. *J Refract Corneal Surg.* Mar-Apr 1994; 10(suppl):S282-4.
292. Riberio JC, McDonald MB, Klyce SD. Photorefractive keratectomy after radial keratotomy in a patient with severe myopia. *Am J Ophthalmol.* Jul 1994; 50(1):106-9.
293. Ring CP, Hadden OB, Morris AT. Transverse keratotomy combined with spherical photorefractive keratectomy for compound myopic astigmatism. *J Refract Corneal Surg.* Mar-Apr 1994; 10(suppl):S217-21.
294. Maloney RK, Chan WK, Steinert RF, Hersh P, O'Connell M. A multicenter trial of photorefractive keratectomy for residual myopia after previous ocular surgery. *Ophthalmol.* Jul 1995; 102(7):1042-53.
295. Meza J, Perez-Santonja JJ, Moreno E, Zato MA. Photorefractive keratectomy after radial keratotomy. *J Cataract Refract Surg.* Sep 1994; 20(5):485-9.
296. Burnstein Y, Hersh PS. Photorefractive keratectomy following radial keratotomy. *J Refract Surg.* Jan-Feb 1996; 12(1):163-70.

297. Lowenstein A, Lipshitz I, Lazar M. Photorefractive keratectomy for the treatment of myopia after epikeratoplasty: A case report. *J Refract Corneal Surg.* Mar-Apr 1994; 10(suppl):S285-6.
298. Gjaltraler R, Trokel SL. Correction of irregular astigmatism with the excimer laser. *Ophthalmol.* Jul 1994; 101(7):1310-5.
299. John ME, et al. Photorefractive keratectomy following penetrating keratoplasty. *J Refract Corneal Surg.* Mar-Apr 1994; 10(suppl):S206-10.
300. Nordan LT, Binder PS, Kassas BS, Heitzmann J. Photorefractive keratectomy to treat myopia and astigmatism after radial keratotomy and penetrating keratoplasty. *J Cataract Refract Surg.* May 1995; 21(3):268-73.
301. Mortensen J, Ohrstrom A. Excimer laser photorefractive keratectomy for treatment of keratoconus. *J Refract Corneal Surg.* May-Jun 1994; 10(3):368-72.
302. Brint SF, et al. Six-month results of the multicenter phase I study of excimer laser myopia keratomileusis. *J Cataract Refract Surg.* Nov 1994; 20(6):610-5.
303. Ganem S, Aron-Rosa D, Gross M, Rosolen S. Myopic keratomileusis by excimer laser on a lathe. *J Refract Corneal Surg.* Sep-Oct 1994; 10(5):575-81.
304. Gomes M. Keratomileusis-in-situ using manual dissection of corneal flap for high myopia. *J Refract Corneal Surg.* Mar-Apr 1994; 10(suppl):S255-7.
305. Pallikaris IG, Siganos DS. Excimer laser in situ keratomileusis and photorefractive keratectomy for correction of high myopia. *J Refract Corneal Surg.* Sep-Oct 1994; 10(5):498-510.
306. Kearns LA. "Homemade" excimer lasers are operating in the US—the rest of the country watches and waits. *J Refract Surg.* Jul-Aug 1995; 11(4):229-33.
307. Ruiz LA, Slade SG, Updegraff SA. Laser in situ keratomileusis (LASIK): Form meets function. *Eyecare Technol.* Mar-Apr 1995; 5(2):67-9.
308. Gilbert ML. LASIK: Beneath the surface. *Eyecare Technol.* Jan 1996; 6(1):47-9.
309. Burrato L, Ferrari M, Genisi C. Myopia keratomileusis with the excimer laser: One year follow-up. *Refract Corneal Surg.* Jan-Feb 1993; 9(1):12-9.
310. Augustine JM. Postoperative advantages of LASIK outweigh intraoperative risks. *Prim Care Optom News.* Mar 1996; 1(2):32.
311. Kremer FB, Gdovin GR. Update of LASIK: Clinical results from 202 eyes. *Rev Optom.* Dec 1995; 132(12): 49-3.
312. Helmy SA, Salah A, Badawy TT, Sidky AN. Photorefractive keratectomy and laser in situ keratomileusis for myopia between 6.00 and 10.00 diopters. *J Refract Surg.* Mar-Apr 1996; 12(2):417-21.
313. Güell JL, Muller A. Laser in situ keratomileusis (LASIK) for myopia -7 to -18 diopters. *J Refract Surg.* Jan-Feb 1996; 12(1):222-8.
314. Reidy JJ, Jacobson MS, Thompson HW, Beuerman RW, Leach DH, McDonald MB. Comparison of corneal epithelial wound healing after photorefractive keratectomy and lamellar keratectomy. *J Refract Surg.* Mar-Apr 1996; 12(2):352-7.
315. Editor. LASIK wins FDA panel nod. *AOA News.* Jul 28, 1997; 36(2):1,6.
316. Editor. FDA warns against marketing LASIK. *AOA News.* Mar 25, 1996; 34(18):1,12.
317. McDonald MB. Excimer lasers: Second generation and beyond. *Eyecare Technol.* Feb 1996; 6(2):55,58, 60,77.
318. Editor. PRK comes to America. *AOA News.* Nov 1, 1995; 34(9):1,10.
319. Van Westenbrugger JA, Gimbel HV. "A comparison of the Summit and VISX excimer lasers: Clinical experience at the Gimbel Eye Center." In: Salz JJ, McDonnell PJ, McDonald MB, eds. *Corneal Laser Surgery.* St. Louis MO: Mosby Year Book Inc; 1995:201-11.
320. Editor. Laser procedures to double this year, survey projects. *AOA News.* Sep 29, 1997; 36(6):8.
321. Tan DTH, Tan JTH. Will patients with contact lens problems accept excimer laser photorefractive keratectomy? *CLAO J.* Jul 1993; 19(3):174-7.
322. Seiler T, Schmidt-Petersen H, Wollensak J. "Complications after myopic photorefractive keratectomy, primarily with Summit excimer laser." In: Salz JJ, McDonnell PJ, McDonald MB, eds. *Corneal Laser Surgery.* St. Louis MO: Mosby Year Book Inc; 1995:131-42.

323. Lohmann CP, Fitzke FW, O'Brart DPS, Kerr-Muir M, Marshall J. Halos—a problem for all myopes? A comparison between spectacles, contact lenses, and photorefractive keratectomy. *Refract Corneal Surg.* Mar-Apr 1993; 9(suppl):S72-5.
324. Zadnick K, Mutti DO. PRK vs. contact lenses: The risk is relative. *Contact Lens Spectr.* Jan 1996; 11(1):12.
325. Schallhorn SC, et al. Preliminary results of photorefractive keratectomy in active-duty United States navy personnel. *Ophthalmol.* Jan 1996; 103(1):5-22.
326. Garber JM. Orthokeratology after PRK: Portend for the future? *Contact Lens Spectr.* Feb 1996; 11(3):37-40.
327. Barraquer C, Cavelier C, Mejia LF. Incidence of retinal detachment following clear-lens extraction in myopia patients. *Arch Ophthalmol.* Mar 1994; 113(3):336-9.
328. Nordan LT. Keratomileusis. *Int Ophthalmol Clin.* Winter 1991; 31(1):7-12.
329. Polit F, Ibrahim O, Maghraby AE, Salah T. Cryolathe keratomileusis for correction of myopia of 4.00 to 8.00 diopters. *Refract Corneal Surg.* Jul-Aug 1993; 9(4):259-67.
330. Slade SG, Updengraff SA. Complications of automated lamellar keratectomy. *Arch Ophthalmol.* Sep 1995; 113(9):1092-3. Letter.
331. Lyle WA, Jin GJC. Initial results of automated lamellar keratoplasty for correction of myopia: One year follow-up. *J Cataract Refract Surg.* Jan-Feb 1996; 22(1):31-43.
332. Guimaraes RQ, Rowsey JJ, Guimaraes MFR, Reis PP, Castro RD, Tirado BR. Suturing in lamellar surgery: The BRA-technique. *Refract Corneal Surg.* Jan-Feb 1992; 8(1):84-7.
333. Charpentier DY, Nguyen-Khoa JL, Diplessix M, Colin J, Denis P. Radial thermokeratoplasty is inadequate for over correction following radial keratotomies. *Refract Corneal Surg.* Jan-Feb 1994; 10(1):34-5.
334. Thompson V. Holmium: YAG laser thermokeratoplasty for correction of astigmatism. *J Refract Corneal Surg.* Mar-Apr 1994; 10(suppl):S293.

APPENDIX A

A. NON-SURGICAL PROCEDURES

ORTHOKERATOLOGY

First practiced in the 1970s, it uses flat, tight-fitting, rigid contact lenses to decrease the curvature and refractive power of the cornea. Progressively flatter lenses are used to mold the cornea. When the cornea sufficiently flattens, “retainer” contact lenses are normally worn intermittently to preserve the modified shape (8). Currently there are studies with PRK patients, with less-than-satisfactory results, who are using orthokeratology to correct their residual myopia (326).

Complications: Keratoconus, ulceration of the cornea, and irregular astigmatism (8).

Advantages: Cornea elasticity and memory allow it to return to its original shape (8).

Disadvantages: Changes to the cornea are not permanent (8).

CYCLOPLEGIA

Used primarily in young children to prevent ciliary spasm caused by near vision, by paralyzing the ciliary muscle, it was thought to prevent the progression of myopia (8). Treatment involved the daily instillation of a cycloplegic in early developing myopes until maturation is complete. Bifocals or reading glasses are used for near vision to prevent further ciliary spasm (8).

Complications: Photophobia due to dilated pupils and exposure to excessive solar radiation (8).

Advantages: None.

Disadvantages: It is difficult to predict which patients are going to develop high myopia. Dilated pupils are cosmetically unsuitable (8).

B. SURGICAL PROCEDURES NOT INVOLVING THE CORNEA

CLEAR LENS EXTRACTION

Developed by Fukula in the 1980s, it was discontinued due to the large number of subsequent retinal detachments. There has been renewed interest in Europe, using modern techniques of crystalline lens extraction and improved intraocular lenses (8).

Complications: Retinal detachments (8,327), cystoid macular edema, posterior capsule opacification, motility disturbances, and secondary glaucoma (8).

Advantages: Initial visual improvements and correction of high degrees of myopia.

Disadvantages: Complications could cause permanent vision impairment (8).

SCLERAL REINFORCEMENT

Introduced by Borley in 1958, it is the only surgical procedure that corrects the cause (axial elongation) rather than the effect of refractive error (8). The procedure consists of strengthening the scleral shell with fascia lata or homologous scleral graft that theoretically curbs the progression of axial elongation (8).

Complications: Anterior uveitis, motility disorders, and retinal detachment (8).

Advantages: Studies have reported that staphylomas (bulging or protrusion of cornea) was reduced and myopic progression was stopped or partially reversed in some patients (8).

Disadvantages: Due to the limited scleral area reinforced by the narrow graft, long-term reports state that some patients have had an increase in myopia (8).

C. SURGICAL PROCEDURES INVOLVING THE CORNEA

KERATOMILEUSIS

Introduced by Barraquer in the mid-1960s (7,328), over 10,000 procedures on myopes have been performed in Colombia (329). Introduced in the United States in 1979 (328), nearly 2,000 procedures have been performed in the United States (329). The procedure is unique in that it was the first time a part of the body was removed, modified, and returned to its original location (9). It consists of removing the anterior two-thirds of the cornea (lamellar keratectomy). The excised corneal tissue is then frozen and cryolathed on the stromal side according to a computer program that has calculated the corneal curvature for the new corneal power, and the lathed autograft is then resutured to the corneal bed (7,8) (see Figure 9). There are currently studies underway using a nonfreeze (thought to avoid corneal damage due to freezing (12)), nonsuture automated lamellar keratectomy (ALK) (11,330).

Complications: Over and under correction (7,10,331), corneal perforation during lathing (7,10), epithelialization of the interface (7,10), irregular astigmatism (7,10,11,12,13,330,331), loss of BCVA (330), infection, corneal opacities (9), healing problems (14), glare (11,13), foreign bodies in interface (13), and endothelial cell loss (13).

Advantages: It can correct very high myopic (i.e., 16.0 - 18.0 D (8)) and hyperopic refractive errors (7,328) even with large anisometropia (8).

Disadvantages: Complexity of procedure, sophisticated equipment (7), cost (12), long post-surgical care (9), reduced quality of vision (9), unpredictability (13), and disk displacement (332).

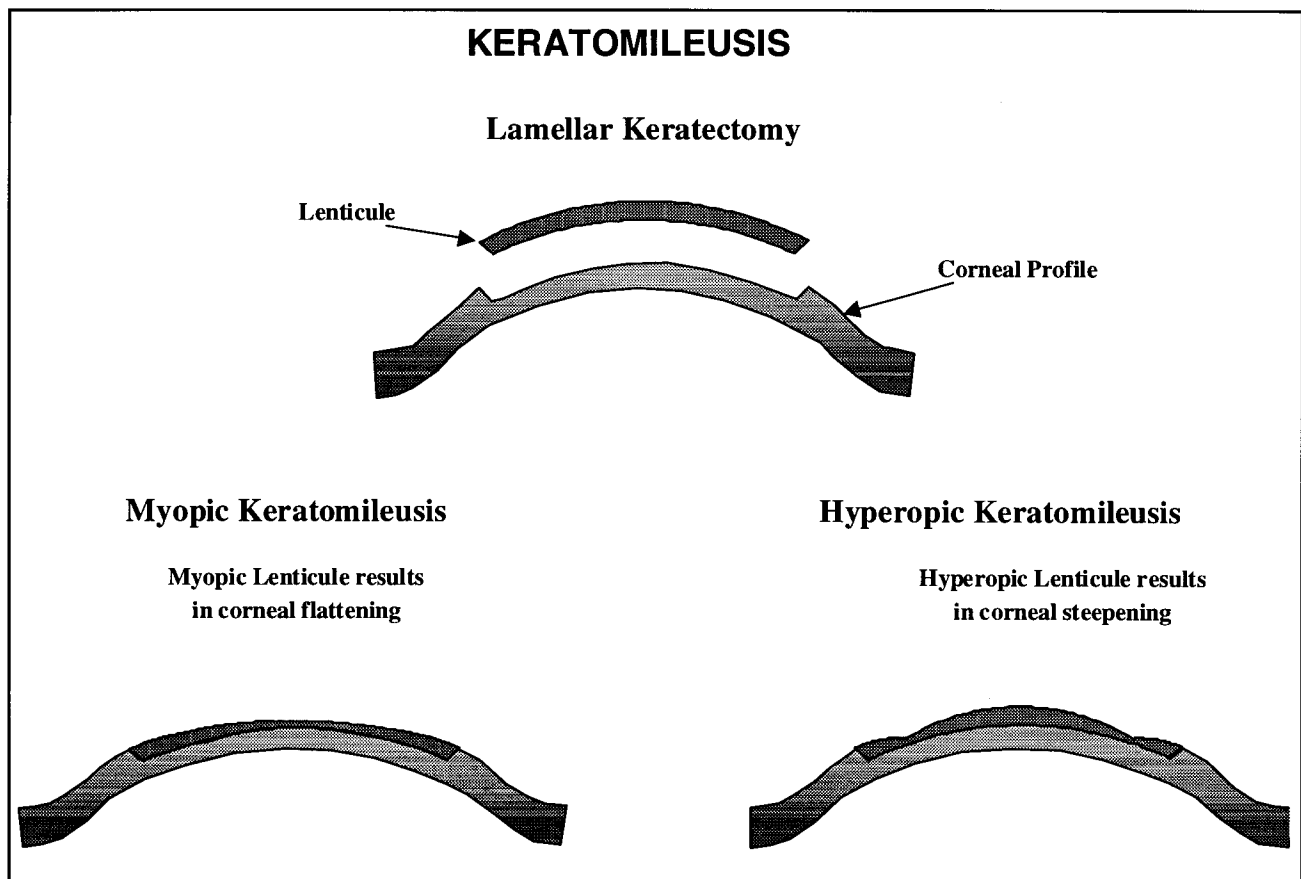


FIGURE 9

KERATOPHAKIA

Introduced by Barraquer in 1980 (7), it consists of a donor corneal tissue to correct aphakic refractive errors by placing an intralamellar plus-powered lenticule in the host cornea. A microkeratome is used to make a lamellar section in the host cornea. The pre-lathed donor lenticule is then centered in the intralamellar space, and the disc is resutured over the lenticule (7) (see Figure 10).

Complications: Induced astigmatism and loss of best-corrected acuity (7).

Advantages: Corrections of $> + 10.0$ D (7) are possible.

Disadvantages: Limited supply of donor corneas and synthetic materials not being well tolerated (7,14).

EPIKERATOPHAKIA

Developed by Kauffman at Louisiana State University, it was originally based on the classic Barraquer procedures of keratophakia and keratomileuses, but it is simpler and safer (7). The procedure consists of lyophilized (freeze-dried) lenticules pre-lathed to correct a particular refractive error. A small epithelial defect is made in the peripheral cornea and a shallow annular keratotomy is performed. The lenticule is rehydrated and the edge of the lens is sutured into the annular keratotomy. After the surgery, the peripheral host epithelium slowly covers the anterior surface of the donor lens (7) (see Figure 11).

Complications: Traumatic separation of the graft in the early healing period, neovascularization, chronic epithelial defects, deposits at the cornea interface, infection (7), and reduced contrast sensitivity (15).

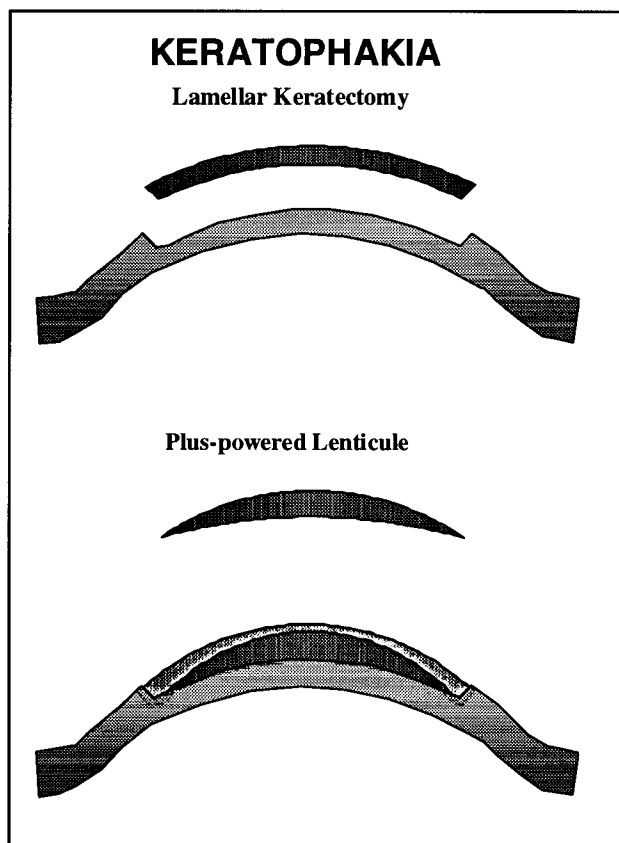


FIGURE 10

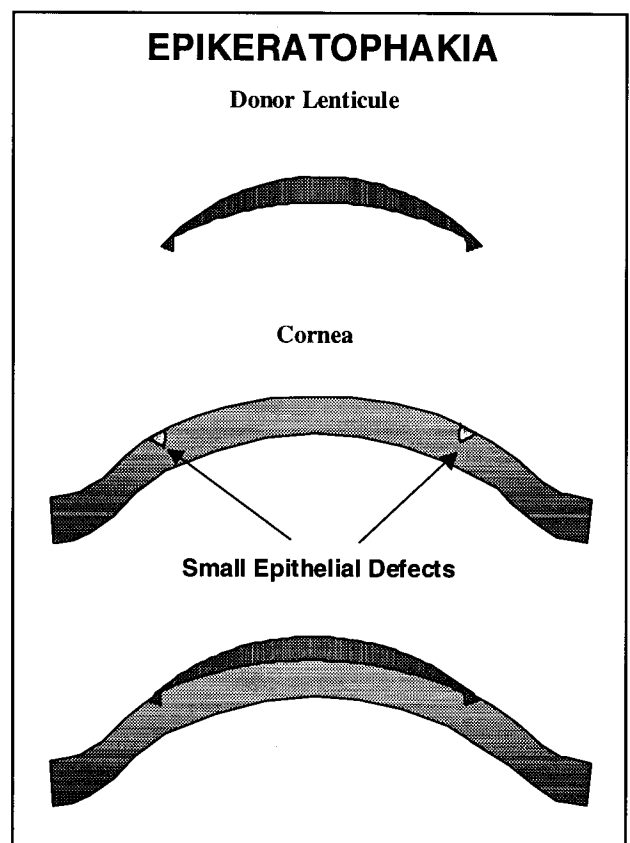


FIGURE 11

Advantages: Treatment of keratoconus and high myopia (14), safety, reversible in-office procedure, no sophisticated instruments (7), and corrected powers up to 37.0 diopters (8).

Disadvantages: Problems with predictability, difficulties with freezing and unfreezing lenticules (14), and centering problems with the lenticules (15).

STROMAL THERMOKERATOPLASTY

Original procedure was introduced by Lans nearly 100 years ago. Gasset and Fyodorov refined the procedure in the 1970s (7). Initially, this procedure consisted of a nichrome tip probe placed at a depth of 80% of the corneal stroma and heated to 600° C for 0.3 seconds to shrink stromal collagen and flatten the cornea (7,16). A modified procedure is undergoing FDA investigational

study using a Holmium:YAG laser as an alternative instrument (17) (see Figure 12). There are other studies using this procedure after RK in patients with disabling spherical hyperopia, but so far results have been less than promising (333).

Complications: Loss of BCVA (17), regression (17), epithelial thinning, Bowman's membrane alterations, recurrent corneal erosions, iritis, and stromal melting (7).

Advantages: It can correct hyperopia and astigmatism (334).

Disadvantages: Failure rate of 50-80% (7) and substantial regression, due to problems controlling the amount and depth of delivered heat (17).

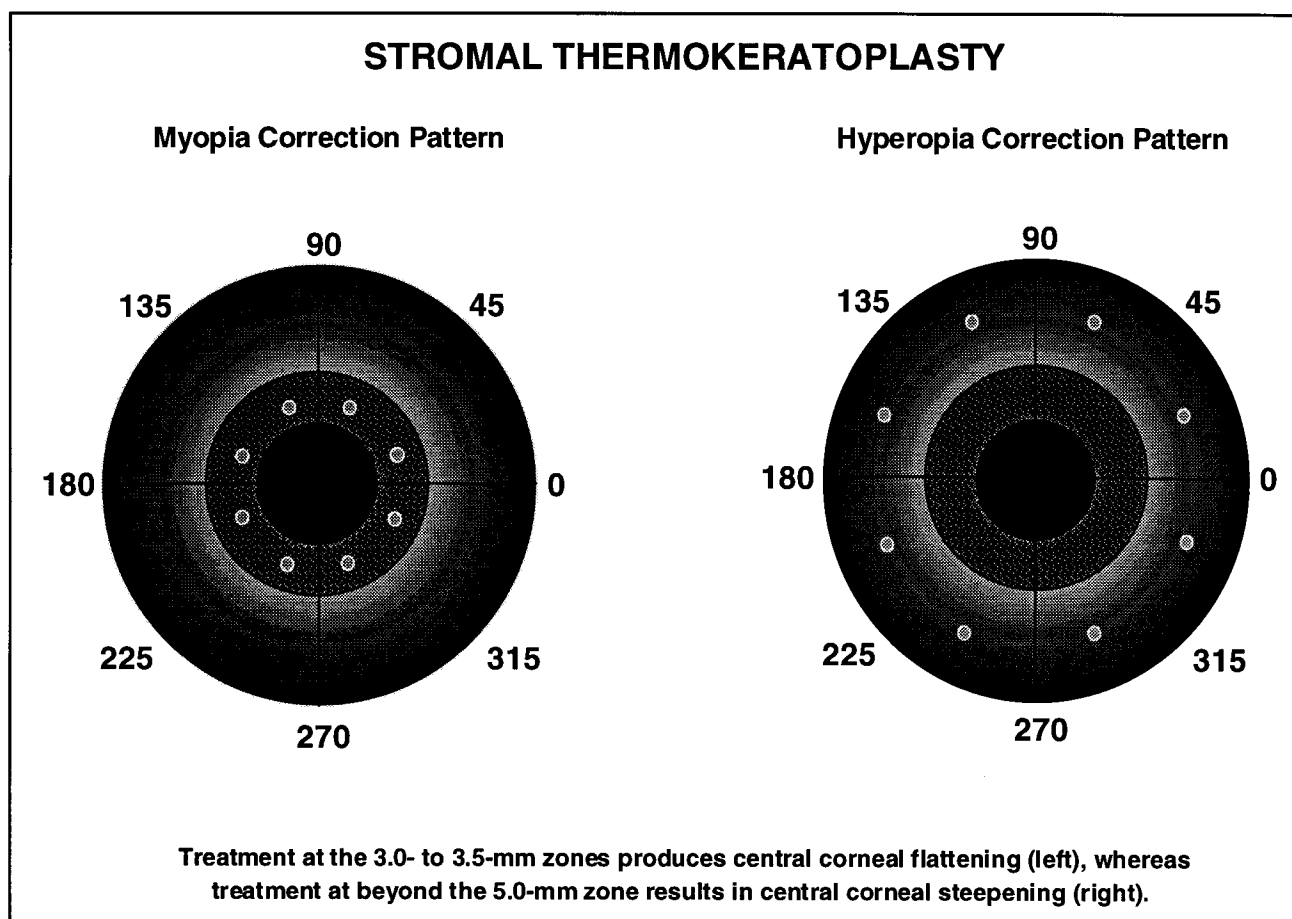


FIGURE 12

INTRASTROMAL CORNEAL RING

A plastic piece is implanted in the mid-peripheral stromal channel, through a small corneal incision, avoiding direct surgical intervention in the central cornea (see Figure 13). Changes in corneal curvature are achieved by varying the thickness of the ring, with increased corneal flattening resulting from increased thickness (18). This procedure is under investigation by the FDA.

Complications: Transient elevated IOP due to corticosteroid use and peripheral haze in the intrastromal channel (18).

Advantages: The procedure is reversible by removing the ring, which results in minimal visual effects since it lies outside the central corneal zone (18,19).

Disadvantages: No known disadvantages are reported, but risks common to corneal surgery exist.

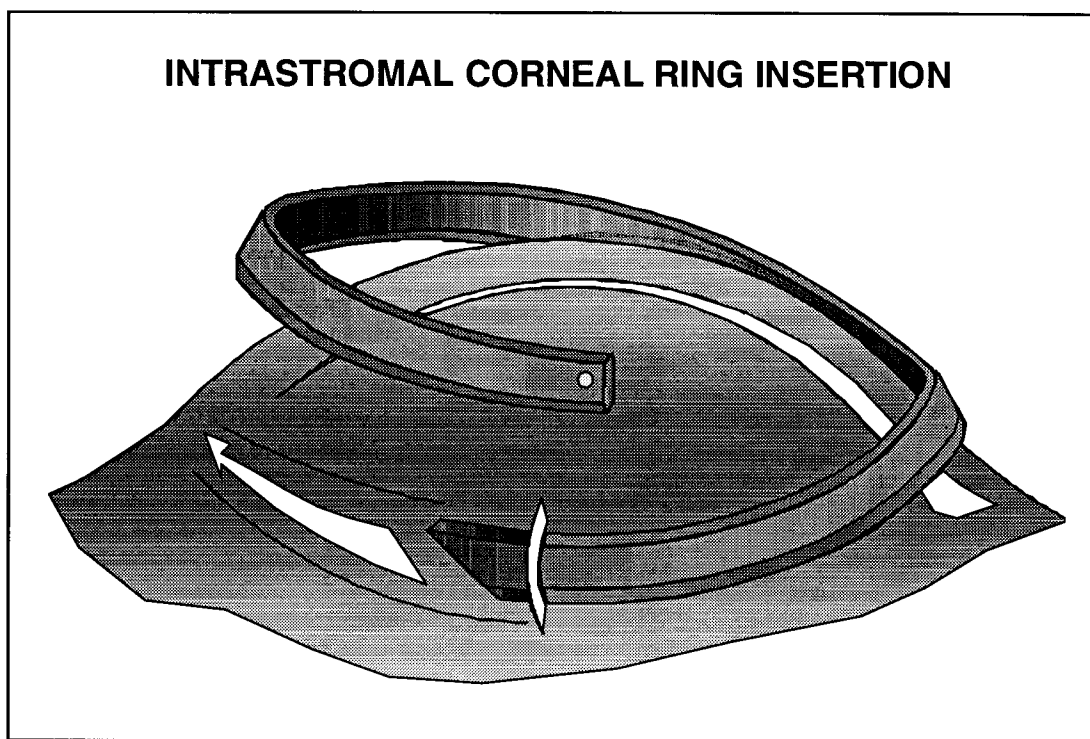


FIGURE 13

