

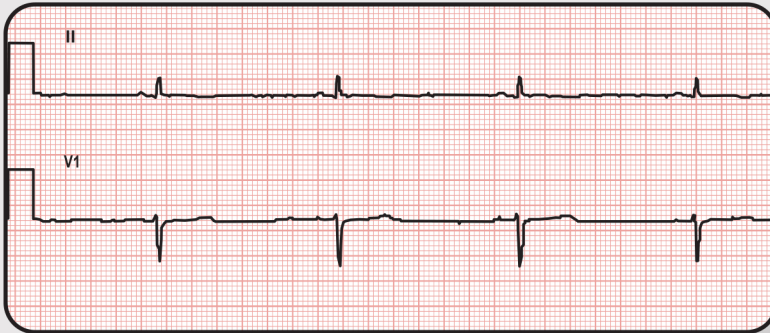
# What are ECG Normal Variants?

page 1 of 6

Many common ECG findings are normal variants and are not cause for deferment, unless the pilot is symptomatic or there are other concerns.



Let's look at a few examples of ECG Normal Variants...



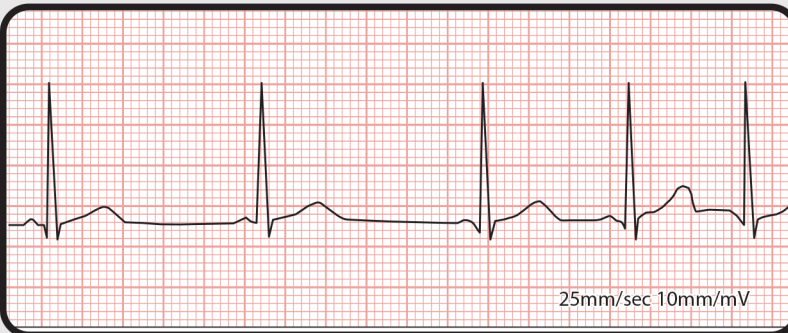
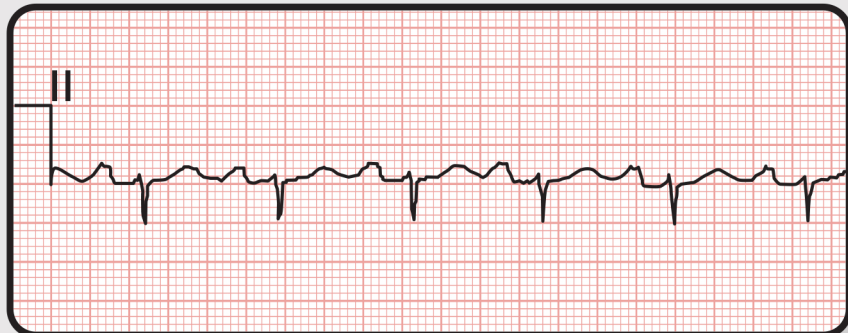
## Sinus Bradycardia

Sinus bradycardia is a normal variant if the pilot is 49 or younger, and their heart rate is greater than 44 beats per minute.

At age 50 and older, their heart rate must be greater than 48 beats per minute.

## Sinus Tachycardia

Sinus tachycardia is a normal variant if the pilot's heart rate is less than 110 beats per minute.



## Sinus Arrhythmia

Sinus arrhythmia is a normal variant.

Aerospace

Medical  
Education

Division

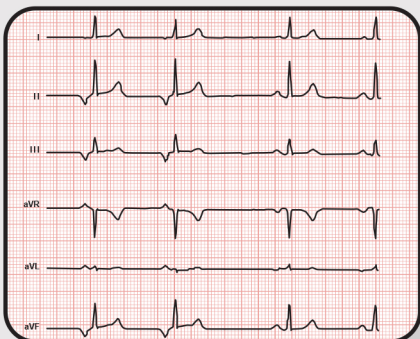
# What are ECG Normal Variants?

page 2 of 6

Many common ECG findings are normal variants and are not cause for deferment, unless the pilot is symptomatic or there are other concerns.



Let's look at a few examples of ECG Normal Variants...

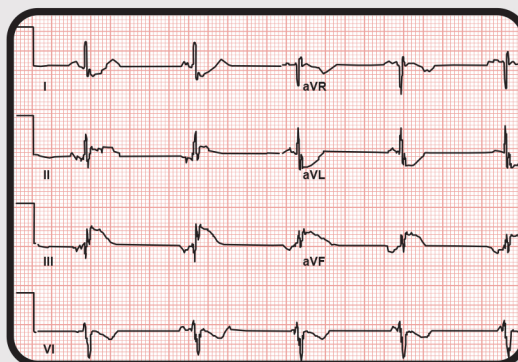


## Low Atrial Rhythm

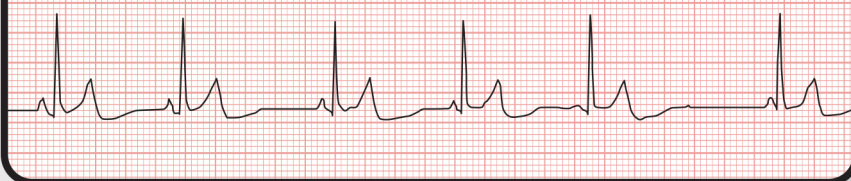Low atrial rhythm is a normal variant when there are upright P waves in the AVR lead, and inverted P's in other limb leads with a short PR interval.

## Ectopic Atrial Rhythm

With ectopic atrial rhythm, the S.A. node rhythm originates in multiple areas of the atria.



Lead II



## Wandering Atrial Pacemaker

A wandering atrial pacemaker looks similar to ectopic atrial rhythm, depending on the interpretive output of your diagnostic equipment.

Aerospace

Medical  
Education

Division



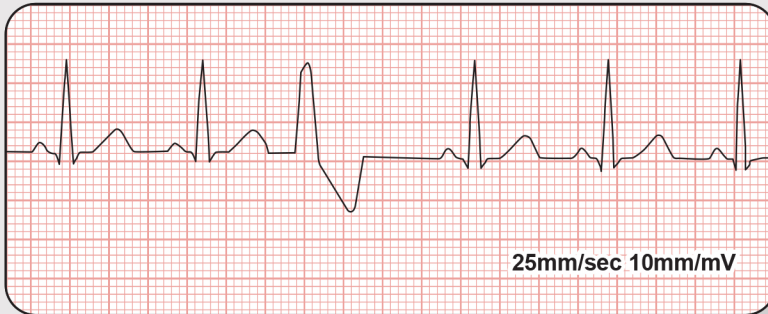# What are ECG Normal Variants?

page 3 of 6

Many common ECG findings are normal variants and are not cause for deferment, unless the pilot is symptomatic or there are other concerns.



**Let's look at a few examples of ECG Normal Variants...**

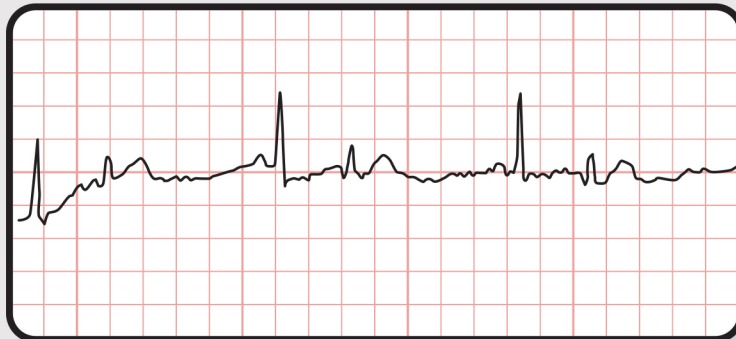


## **Single Premature Ventricular Contraction**

A single premature ventricular contraction (PVC) is a normal variant. However, two or more PVCs on a 12-lead ECG would require a workup.

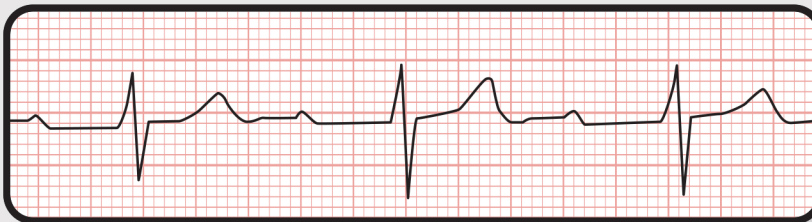
## **Two Or More Premature Atrial Contractions In A Pilot Less Than 50 Years Old**

This is a normal variant unless the pilot is symptomatic.



## **First-degree AV Block With PR Interval Between 0.21 and 0.29 Seconds**

Any first-degree AV block with a PR interval 0.21 to 0.29 seconds is a normal variant. Any PR interval greater than 0.30 requires an evaluation.



Aerospace

Medical  
Education

Division

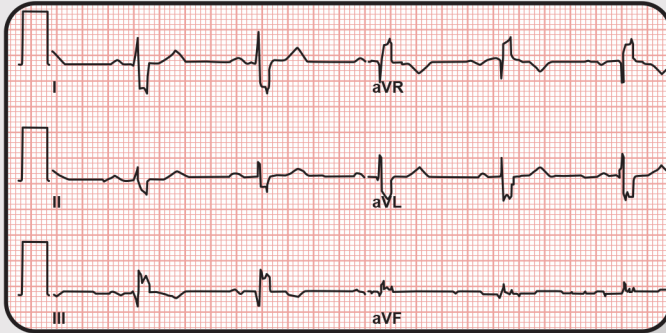
# What are ECG Normal Variants?

page 4 of 6

Many common ECG findings are normal variants and are not cause for deferment, unless the pilot is symptomatic or there are other concerns.



**Let's look at a few examples of ECG Normal Variants...**



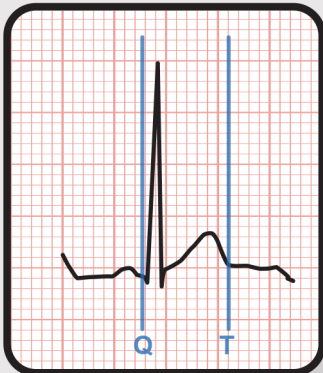
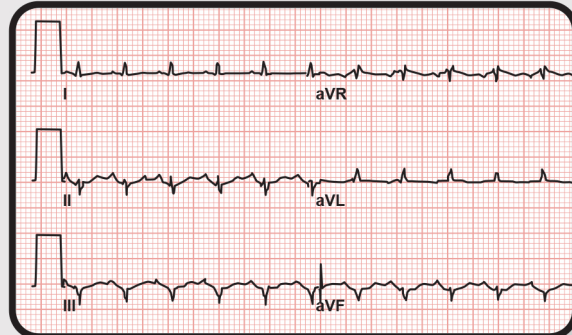
## **Indeterminate Axis**

An indeterminate axis is a normal variant and does not require a workup.

## **Low Voltage Electromotive Force**

Low voltage in the limb leads is a normal variant and does not require a workup.

Note: Make sure the ECG is performed with 10mm standardization.



## **Short QT Interval**

A short QT interval is a normal variant as long as there is no history of arrhythmia.

Aerospace

Medical  
Education

Division



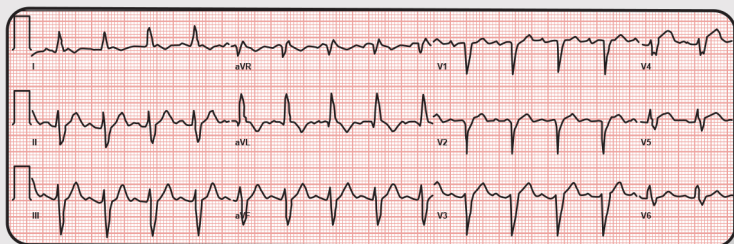
# What are ECG Normal Variants?

page 5 of 6

Many common ECG findings are normal variants and are not cause for deferment, unless the pilot is symptomatic or there are other concerns.



Let's look at a few examples of ECG Normal Variants...



## Intraventricular Conduction Delay (IVCD) (Complexes do not appear like a Rt or Lt BBB)

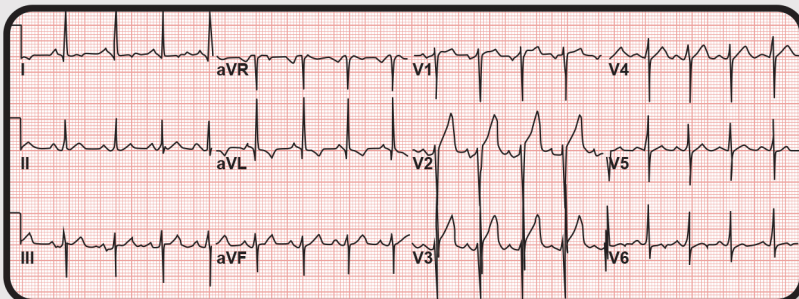
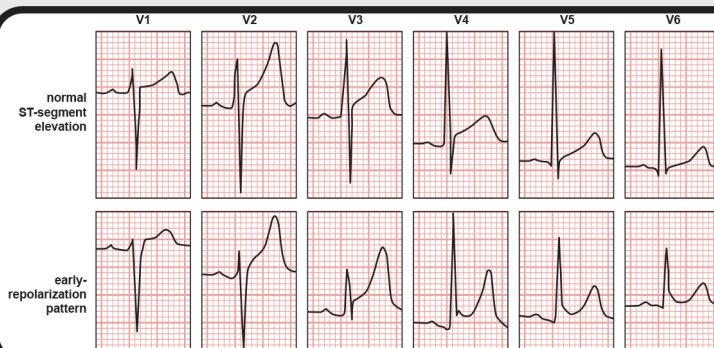
Abnormally wide QRS complex

Intraventricular conduction delay is when the QRS complex is greater than or equal to 0.12 seconds and does not appear like a right or left bundle branch block.

## Early Repolarization

(Defined as appearance of a J wave on a normal heart beat pattern)

Early repolarization appears as elevation of the J point or ST where the ST segment is concave up. It is more prevalent in younger persons.



## Left Ventricular Hypertrophy By Voltage Criteria Alone

Left ventricular hypertrophy by voltage criteria alone is a normal variant.

Aerospace

Medical  
Education

Division

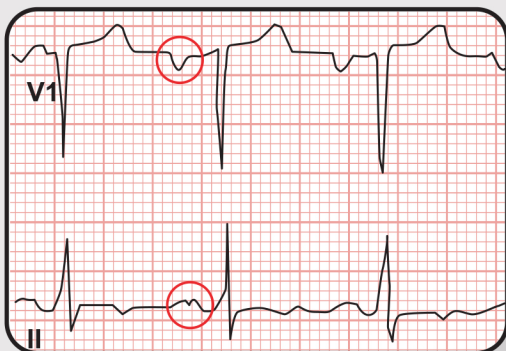# What are ECG Normal Variants?

page 6 of 6

Many common ECG findings are normal variants and are not cause for deferment, unless the pilot is symptomatic or there are other concerns.



Let's look at a few examples of ECG Normal Variants...



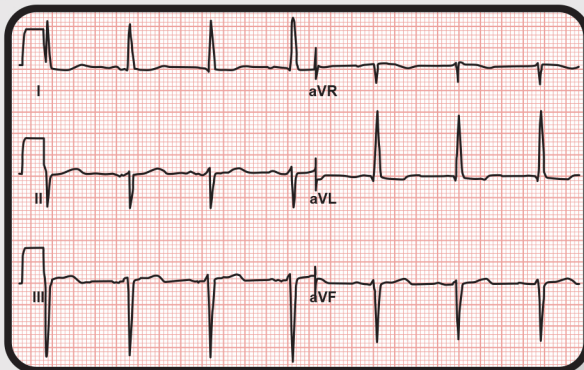
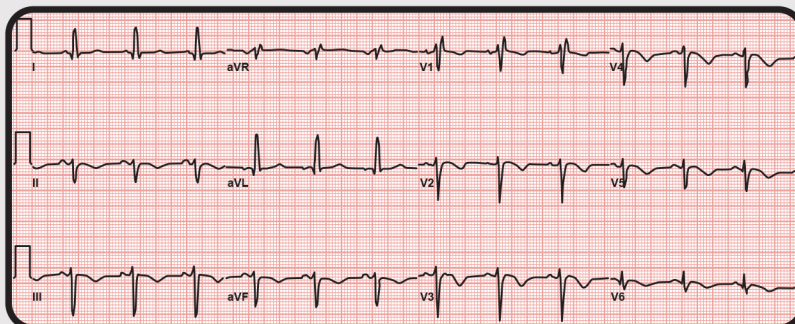
## Left Atrial Enlargement

Left atrial enlargement by ECG criteria is likely also a normal variant.

## Incomplete Right Bundle Branch Block (IRBBB)

An incomplete right bundle branch block is an RSR pattern that is 0.10 to 0.11 seconds, or stated differently, is a QRS complex duration less than 0.12 seconds.

This is quite common in healthy people.



## Left Axis Deviation (less than or equal to -30 degrees)

Left axis deviation is a condition where the mean electrical axis of ventricular contraction of the heart lies in a frontal plane direction between negative 30 degrees and negative 90 degrees. This is reflected by a QRS complex positive in lead one and negative in leads aVF and two.

Aerospace

Medical  
Education

Division